

Nitish Chourasia MD <sup>1</sup>, Michael Quach MD <sup>1</sup>, Jay Gavvala MD, MSCI <sup>2</sup>  
Departments of <sup>1</sup>Pediatric Neurology and <sup>2</sup>Adult Neurology, Baylor College of Medicine, Houston, Texas, United States

## Background & Objective

- Insular epilepsies are notoriously difficult to diagnose and frequently imitate frontal, temporal and parietal lobe epilepsies.
- MEG has been shown to be an effective diagnostic tool in identifying insular epilepsies.
- However, in the current clinical workflow, it is unclear if the MEG dipole clusters (DC) could represent possible benign variants or indicate primary epileptogenic zone vs a secondary epileptogenic network.
- We identify patients with MEG based insular involvement in refractory epilepsy and describe their clinical and MSI characteristics to evaluate the following:
  - Do insular dipole clusters (DC) in MEG represent normal variants?
  - Does the presence of insular MEG DC imply a primary insular onset epilepsy?
  - Does an insular MEG DC focus correlate with seizure outcomes after surgical intervention involving the insula?

## Methods

- The database for magnetic source imaging (MSI) studies for patients with refractory focal epilepsy completed at Baylor College of Medicine affiliates St. Luke's Hospital and Texas Children's Hospital from 2015-2018 was retrospectively evaluated.
- All patients with MEG insular dipole clusters (> 5 spikes) on MSI reports, including a subset of patients who underwent subsequent epilepsy surgery with a minimum follow up of six months were evaluated.
- Primary dipole clusters were designated as group of MEG spikes most frequently seen.
- Data obtained included age, sex, seizure semiology, age of seizure onset, seizure frequency, MRI brain, EEG and MEG findings (primary vs secondary cluster), surgical approach- (stereotactic EEG (SEEG)/ subdural grids), inclusion of insular coverage and presence of insular spikes on intracranial EEG, region of resection/laser ablation and seizure frequency post-operatively.

## Results

- A total of 36 out of the 319 (11.3%) patients had MEG DC localized to the insula (among other regions).
- This included 20 (55.6%) adults and 16 (44.4%) children (age ≤ 18).
- Mean age was 22 ± 13.44 years with 17 (47.2%) females and 19 (52.8%) males.
- Nineteen (52.8%) patients had primary insular DC and 17 (47.2%) had secondary insular DC.
- Twenty-four (66.7%) patients had some form of surgical intervention, while twelve (33.3%) were in the pre-surgical evaluation phase at the time of this review.
- Sixteen patients had intracranial epilepsy surgical evaluation (14 SEEG and 2 subdural grids).
- Out of the 14 SEEG cases, 11 had targeted insular coverage while 3 did not.
- Ten (90.9%) of the 11 patients with insular coverage by SEEG electrodes had interictal insular spikes during intracranial electrocorticography monitoring.
- In five (45.5%) of these 11 patients, the insula was identified to constitute the ictal onset zone based on intracranial EEG data.

Figure 1. Illustrative example of MEG dipole cluster localization and intracranial EEG

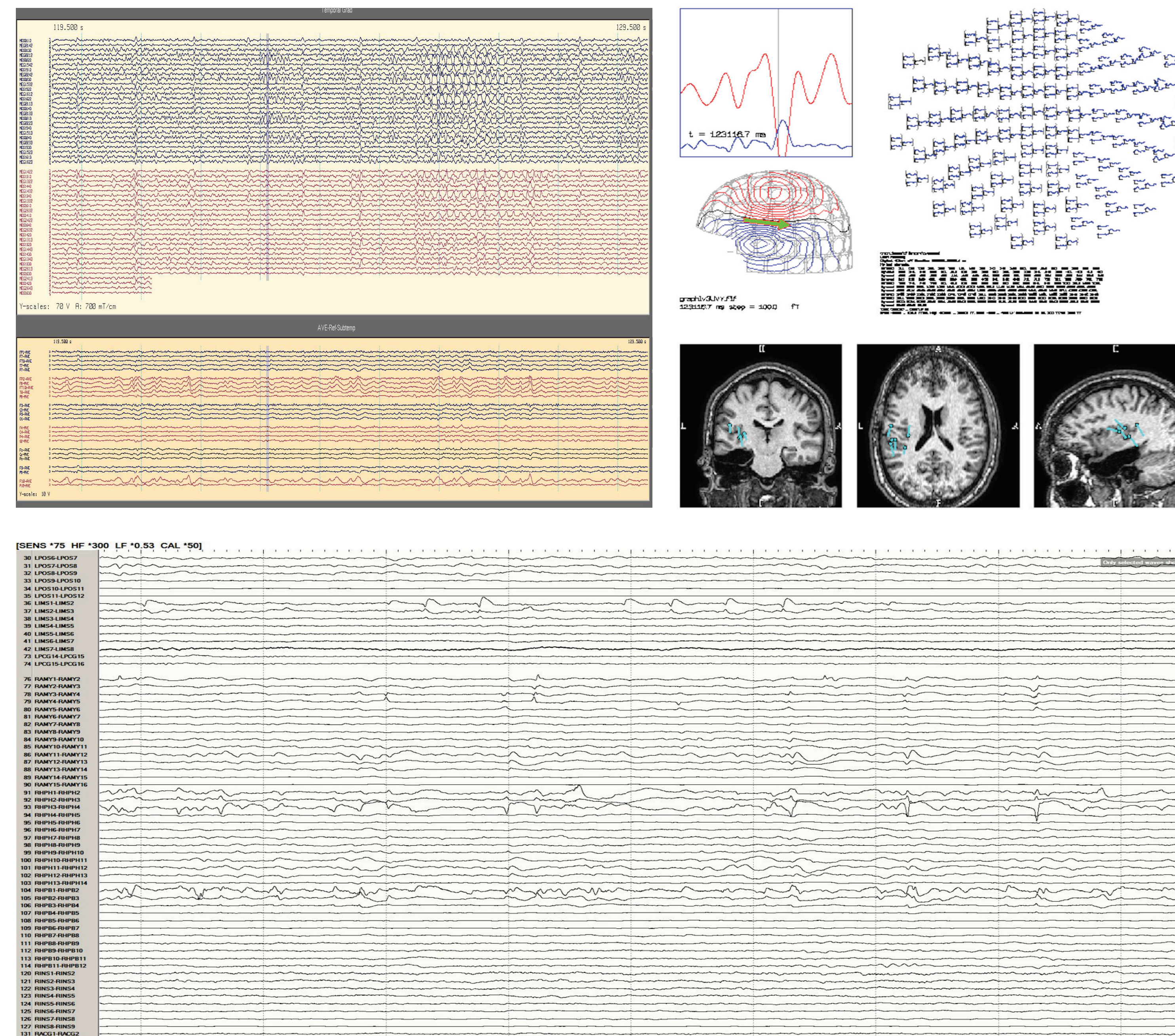


Table 1. Surgical outcomes in insula vs non-insula intervention

Engel Outcomes	Intervention (Resection, Ablation)	
	Involving Insula	Not Involving Insula
I	3	4
II	2	4
III		1
IV		1



Contact Information:  
Jay Gavvala, MD, MSCI  
7200 Cambridge 9A  
Houston, TX 77030  
Jay.Gavvala@bcm.edu

Table 2. Clinical characteristics of patients with MEG insular DC and intracranial evaluation

Serial #	Age (y)	Sex	Seizure Types	EEG	MRI	MEG Insular cluster (1* vs 2*)	Phase II (Insular coverage)	Phase II (Interictal) Insula	Phase II (Ictal) Insula	Intervention	Intervention involving Insula	Engel Outcome
1	6	F	Behavioral arrest; Myoclonic; Tonic	Left hemisphere (temporal-parietal)	Left PVNH	Y (P)	Y	Y	N	Left frontal resection	N	IV
2	10	F	Gelastic; Behavioral arrest w focal motor	Generalized spike wave	HH (prior ablation)	Y (S)	Y	Y	Y	None (Broad network)	N	-
3	14	F	Behavioral arrest; focal right motor to b/ tonic-conic	Left frontal-central	Multiple cortical tubers	Y (S)	N*	N	N	Left fronto-temporal resection	N	II
4	6	M	Gelastic; Behavioral arrest	Left posterior temporal-occipital	HH	Y (S)	Y	Y	N	Left temporal w HH ablation	N	I
5	3	M	Focal motor tonic	Right anterior temporal, frontal	Multiple cortical tubers	Y (P)	Y	Y	Y	Ablation of insular-opercular tuber focus	Y	II
6	45	M	Focal sensory	Right temporal	Right mesial temporal s/p resection	Y (S)	Y	Y	Y	Resection (Right orbitofrontal w insula)	Y	II
7	24	M	Focal sensory w hypermotor motor	Non-localizing	Normal	Y (P)	Y	Y	Y	RNS middle and posterior insula	Y	I
8	22	F	Focal sensory, autonomic	Left frontal	Normal	Y (P)	N*	N	N	Left frontal resection	N	II
9	32	M	Behavioral arrest, Focal automatisms	Right temporal	Right MTS	Y (S)	Y	Y	N	RNS right hippocampus	N	IV
10	32	F	Autonomic hypermotor	Right lateralized	Right frontal-parietal encephalomalacia	Y (S)	Y	Y	Y	Right frontal resection	Y	I
11	33	F	Behavioral arrest	Right anterior temporal	Normal	Y (P)	Y	Y	N	Right temporal lobectomy	N	I
12	34	F	Focal sensory, behavioral arrest	Right anterior temporal	Prior partial right temporal resection	Y (S)	Y	Y	N	Right temporal lobectomy	N	II
13	58	F	Behavioral arrest	Left frontal, temporal	Left temporal pole encephalomalacia	Y (S)	Y	N	N	Left orbitofrontal focus w temporal lobectomy	N	II
14	33	M	Behavioral arrest	Right fronto-polar and left temporal	Right inferomedial temporal lobe w gliosis	Y (S)	N	N	N	None (Broad network)	N	-
15	8	M	Behavioral arrest, left motor	Right fronto-central; right occipital	Multifocal cortical tubers	Y (S)	N	N	N	Focal tuber ablation frontal and occipital	N	-
16	36	M	Behavioral arrest w automatisms	Left temporal	Left PVNH	Y (S)	N	N	N	Bi-temporal RNS	N	III

M = Male, F = Female, HH = Hypothalamic hamartoma, PVNH = Periventricular nodular heterotopia, Y = Yes, N = No, P = Primary, S = Secondary, RNS = Responsive neurostimulation, VNS = Vagal nerve stimulation, FCD = Focal cortical dysplasia, GTC = Generalized tonic clonic. \*Subdural grids

## Highlights & Conclusions

- Out of 11 patients with MEG DC in the insula who underwent intracranial EEG monitoring, 5 were determined to have an ictal onset zone including the insula (45.5%)
- Insular DC identified on surface MEG were also noted with intracranial stereotactic EEG depth electrode contacts in the insula.
- The presence of insular MEG DC however, may not definitively imply a primary insular onset epilepsy but likely reflect the extent of epileptogenicity within the ictal network.
- Patients with MEG DC that underwent resection/ablation that did not include the insula had no worse of an outcome as compared to ones where insula was included in the resection or ablation.
- Targeted evaluation of the insula with SEEG may help understand the role of insula within the epileptogenic network.

## References

- Heers M, Rampp S, Hermann S. MEG-based identification of the epileptogenic zone in occult peri-insular epilepsy. *Seizure*. 2012; 21(2): 128-33.
- Mohamed IS, Gibbs SA, Robert M et al. The utility of MEG in the presurgical evaluation of refractory insular epilepsy. *Epilepsia*. 2013; 54(11): 1950-9.
- Laoprasert P, Ojemann JG, Handler MH. Insular epilepsy surgery. *Epilepsia*. 2017; 58(1): 35-45.
- Bagic A, Knowlton R, Rose D et al. American Clinical Magnetoencephalography Society Clinical Practice Guideline 1: recording and analysis of spontaneous cerebral activity. *J Clin Neurophysiol*. 2011; 28(4): 348-54.