

OBJECTIVES

✓To evaluate the relationship between verbal and visual memory and unilateral white matter tract integrity using diffusion tensor imaging (DTI) in individuals with intractable temporal lobe epilepsy (TLE).

BACKGROUND

- ✓Verbal memory impairment is consistently found in individuals with left-sided TLE. Though less frequently replicated, visual memory impairment is found in individuals with right-sided TLE.¹
- ✓Decreased diffusion anisotropy has been demonstrated in white matter tracts of adults with TLE. Recently, two studies^{2,3} reported an association between verbal memory impairment and decreased fractional anisotropy (FA) of the left uncinate fasciculus (UF), parahippocampal cingulum (PC), or inferior fronto-occipital fasciculus (IFOF) in patients with TLE.
- ✓It is unclear whether visual memory is associated with right-sided white matter tract integrity.

PARTICIPANTS


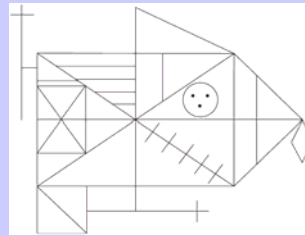
Six patients diagnosed with video/EEG defined intractable TLE (3 left, 3 right) underwent neuropsychological assessment and DTI. FA was computed for all tracts involving the temporal lobe using AFNI and the ICBM WM Atlas (See poster #P09.065 for a detailed description of DTI analyses). Table 1 shows the demographic and disease-related data for the sample.

Table 1. Sample characteristics

	Left-TLE		Right-TLE	
	M	SD	M	SD
Chronological Age (yr.)	38.3	14.9	28.0	8.8
Education (yr.)	12.3	1.6	12.7	1.2
Seizure Frequency (mo.)	6.7	4.2	21.3	15.0
Age at Onset (yr.)	22.7	4.2	10.7	8.4
Duration of Illness (yr.)	14.0	15.8	17.0	9.5

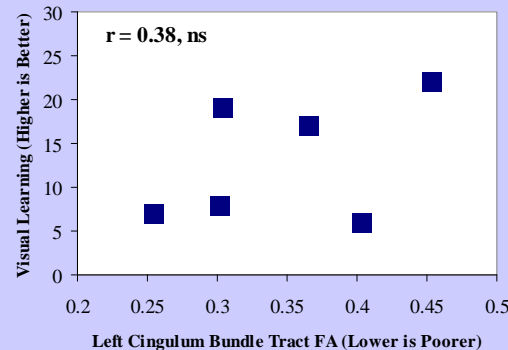
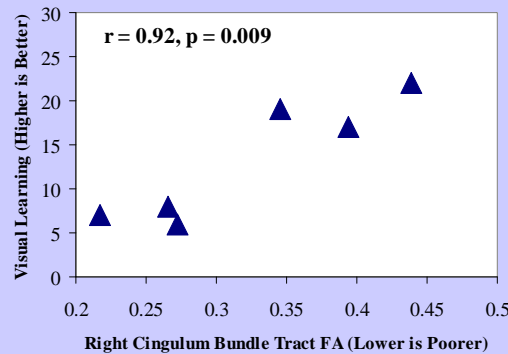
METHODS

Episodic memory tasks included the Rey-Osterrieth Complex Figure Test (Rey, 1941; Osterrieth, 1944) and Buschke Verbal Selective Reminding Test (Buschke & Fuld, 1974).



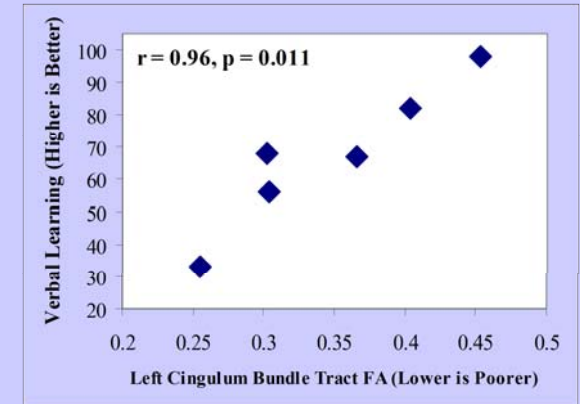
RESULTS (Figures 1 and 2)

Visual recall was not associated with FA of the right UF, PC or IFOF. However, poorer visual recall was significantly associated with decreased FA of the right cingulum bundle, but not the left cingulum bundle (CB).



RESULTS (Figure 3)

Poorer verbal recall was associated with decreased FA of the left CB, but not the right CB.



CONCLUSIONS / RELEVANCE

- ✓Our findings constitute a double dissociation: reduced right CB integrity is related to impaired visual memory but not verbal memory, whereas reduced left CB integrity is related to impaired verbal memory but not visual memory.
- ✓The cingulum bundle connects the frontal and temporal lobes, and is thought to be associated with attention, error detection, mental flexibility, problem solving, learning, and emotion regulation.⁴
- ✓Results suggest that disturbances of white matter integrity of fronto-temporal pathways are related to material specific retrieval difficulties in TLE.

REFERENCES

1. Dulay MF, York MK, Soety EM, Hamilton WJ, Mizrahi EM, Goldsmith IL, Verma A, Grossman RG, Yoshor D, Armstrong DD, Levin HS. Memory, emotional and vocational impairments before and after anterior temporal lobectomy for complex partial seizures. *Epilepsia*, 2006 Nov;47(11):1922-30.
2. McDonald CR, Ahmadi ME, Hagler DJ, Tecoma ES, Iragui VJ, Gharapetian L, Dale AM, Halgren E. Diffusion tensor imaging correlates of memory and language impairments in temporal lobe epilepsy. *Neurology*, 2008 Dec 2;71(23):1869-76.
3. Yogarajah M, Powell HW, Parker GJ, Alexander DC, Thompson PJ, Symms MR, Boulby P, Wheeler-Kingshott CA, Barker GJ, Koeppe MJ, Duncan JS. Tractography of the parahippocampal gyrus and material specific memory impairment in unilateral temporal lobe epilepsy. *Neuroimage*, 2008 May 1;40(4):1755-64.
4. O'Sullivan M, Barrick TR, Morris RG, Clark CA, Markus HS. Damage within a network of white matter regions underlies executive dysfunction in CADASIL. *Neurology*. 2005 Nov 22;65(10):1584-90.