

Introduction

Recently, a Parkinson's disease (PD)-related cognitive pattern (PDCP) was identified using positron emission tomography, characterized as decreased metabolism in prefrontal and parietal association areas and hypermetabolism in the cerebellar vermis and dentate nuclei. It is unclear whether the PDCP is accompanied by structural changes in these structures.

Diffusion Tensor Imaging (DTI) is a novel neuroimaging technique that estimates myelination *in vivo*. Using the principal that water molecules tend to move faster along nerve fibers rather than perpendicular to them.

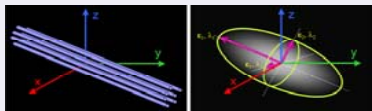


Figure 1: Schematic representation of diffusion displacement for the diffusion tensor.


Our objective was to investigate the neurobiological mechanisms of cognitive impairment in PD by evaluating the relationship between cognitive performance and whole brain DTI.

Methods

6 PD patients and 6 healthy controls (HC) were evaluated using DTI voxel based approach for whole brain analysis and neuropsychological evaluation. DTI dataset were acquired in axial orientation covering the whole brain in contiguous 3 mm slices in 15 directions. Fractional anisotropy (FA) and apparent diffusion coefficient (ADC) were analyzed for right and left hemisphere cortical, subcortical and cerebellar areas.

Table 1: Demographics

	PD	HC
Gender	67/33	50/50
Age	67.5 (4.3)	62.7 (7.2)
Education	12.8 (2.9)	15.7 (2.3)
H&Y off	2.0 to 3.0	NA



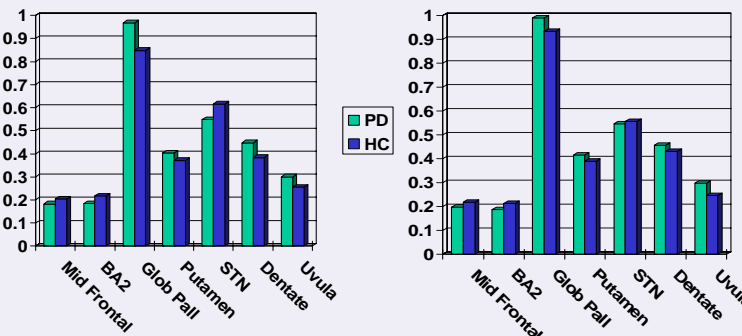
Results

A typical pattern of PD cognitive impairments was found, including deficits in mental status, verbal and nonverbal memory and executive functioning.

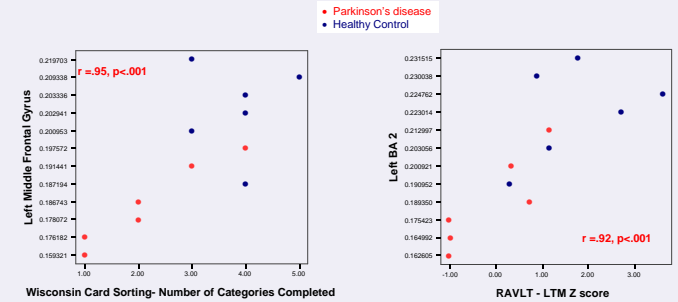
In PD patients compared to HC, the left middle frontal gyrus, left somatosensory white matter and left subthalamic nucleus showed significantly decreased FA.

The left globus pallidus, left putamen, and bilateral cerebellar uvula demonstrated increased FA for the PD patients. ADC was significantly increased in the left cerebellar dentate for the PD patients.

Figure 2a and b: Left and Right Hemisphere FA for PD and HC



Results



For the PD patients, lower FA in the left middle frontal gyrus was significantly correlated with executive functioning impairment, and lower FA in the left somatosensory area was correlated with long-term verbal memory impairment.

Discussion

In this preliminary study, voxel based DTI demonstrated changes in several areas associated with the PDCP. The left middle frontal gyrus, left parietal association area, and bilateral cerebellum showed differences in DTI indices between the PD and HC groups. Striatal and subcortical structures also demonstrated significant group differences.

Changes in frontal and parietal areas were related to poor executive functioning and verbal memory performance for PD patients.

These findings suggest that changes in these brain areas may mediate the common cognitive pattern in PD.

Future research will incorporate larger sample sizes and will compare cognitively intact and impaired PD groups.

ACKNOWLEDGMENT: This research was supported by NIH/NINDS K23, The Methodist Hospital Research Institute, Veterans Affairs, Office of Research and Development.

