

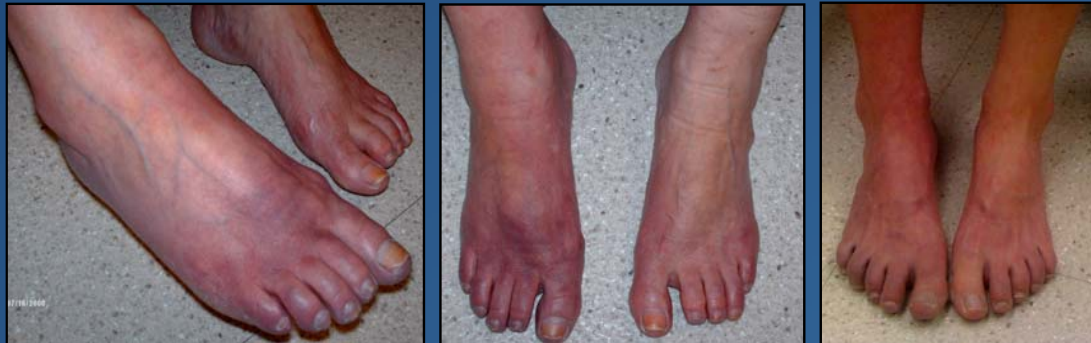

Introduction: Autonomic dysfunction (AD) in multiple sclerosis (MS) has been recently reported, mostly affecting bladder, bowel, sexual and sweat organs. Orthostatic dizziness has been found in 50% of MS patients. Until now, studies had focused more on cardiovascular reflex testing and blood pressure responses. Autonomic manifestations may be subclinical when abnormal sympathetic skin response or decreased heart rate variation is estimated. We report 28 MS patients with discoloration in lower extremities which was not associated with vascular or other concomitant disease.

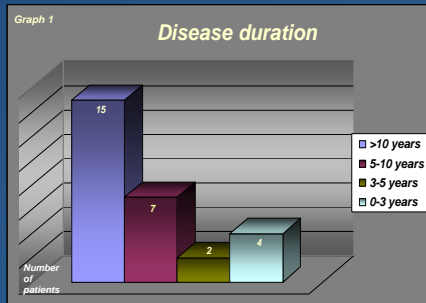
Objective: To describe a group of MS patients who developed distinctive discoloration in distal lower extremities.

Methods: Lower limb discoloration was noticed in MS patients during their follow up visit at the Maxine Mesinger Comprehensive Care Center. Epidemiologic data, treatment history, type of MS and disease duration were documented. Patients with concomitant disease (DM, vascular insufficiency) were excluded. Complete physical and neurologic exam were performed. Some patients were evaluated with arterial doppler.

Results: A total of 28 MS patients were enrolled, 25 women with a mean age of 52. Demographic information presented in table 1. 80% were currently on treatment with a disease modifying agent. All patients demonstrated distal discoloration of lower extremities; peripheral pulses were normal in all patients. Coloration did not change with leg raising. 11.5% had dysautonomic symptoms. 3 patients were evaluated with arterial doppler evaluation: all were normal. Current treatments are presented in table 2. Disease duration is presented in graph 1. EDSS ranged between 2 to 7 with an average of 4.5.



Demographics Table 1		Current treatment Table 2	
Patients n 28		Copaxone	9
Women	25	Tysabri	5
Men	3	Avonex	3
Caucasian	24	Rebif	2
Hispanic	3	Methotrexate	3
African American	1	Betaseron	2
Type of MS		Not currently treated	4
RRMS	21		
SPMS	6		
PPMS	1		



Conclusions: AD is seldom recognized by MS patients; it can cause paroxysmal arrhythmias, recurrent syncope, neurogenic pulmonary edema and decreased ventricular ejection fraction, leading to increased morbidity and mortality. MS can involve any part of the CNS, including critical areas subserving autonomic function causing interference of descending autonomic pathways during their course in the brainstem or spinal cord. Demyelinating lesions located among central thermoregulatory pathways may result in regional or global anhidrosis in patients with MS. Skin changes could be a manifestation of AD which may reflect an impact on the quality of life in MS patients.

*Carl-Abercht Autonomic dysfunction in multiple sclerosis, J Neurol 2006; 253 Suppl 1.
 *Dilek Ince Gural, Nazire Afisar, Tulin Tanridag, Autonomic dysfunction in Multiple Sclerosis: Correlation with disease related parameters, 2002, Eur Neurol 48:1-5.
 *Acevedo AR, Nava C, Cardiovascular dysfunction in multiple sclerosis, 2000 Acta Neurol Scand 101:85-88
 *Bosma R, Wynia K, Hvikoba E, Efficacy of desmopressin in patients with multiple sclerosis suffering from bladder dysfunction: a meta analysis, Acta Neurol Scand 112:1-5
 *El-Maghraby TA, Shalaby NM, Tawdy MK, 2005, Gastric motility dysfunction in patients with multiple sclerosis assessed by gastric emptying scintigraphy, Can J Gastroenterol 19:141-145
 *De Seze J, Stojkovic T, Bauvrit JY, Autonomic dysfunction in multiple sclerosis: Cervical spinal cord atrophy correlates, J Neurol 2001;248:297-303.