Transverse Spinal Cord Infarct in a 15 Year Old Male Following Lumbar Epidural Catheter Placement

Daniel Savitt, DO, Davut Pehlivan, MD, Sarah Risen, MD
Baylor College of Medicine

Background

Spinal cord infarctions are extremely uncommon in children and the etiology is often unknown. The occurrence of transverse spinal cord infarct is even more rare. Etiologies include diseases or procedures involving the aorta, intrinsic arterial occlusion and hypoperfusion. To our knowledge, this is the first case of transverse spinal cord infarction in the pediatric population possibly due to lumbar epidural catheter placement.

Objectives

Describe a case of transverse spinal cord infarction occurring after placement of a lumbar epidural catheter for pain management.

Methods

A 15 year old male with a history of renal transplant due to ESRD secondary to chronic glomerulonephritis underwent ureteral transposition over a crossing renal artery that was causing compression of the ureter. Subsequently, a lumbar epidural catheter was placed for postoperative pain control. There were no documented periods of systemic hypotension nor other immediate complications. Shortly thereafter, the patient developed bilateral lower extremity flaccid paraplegia and sensory loss.

Imaging

Figure 1 (left): T2-weighted axial MRI demonstrating almost entire involvement of transverse section of the spinal cord.

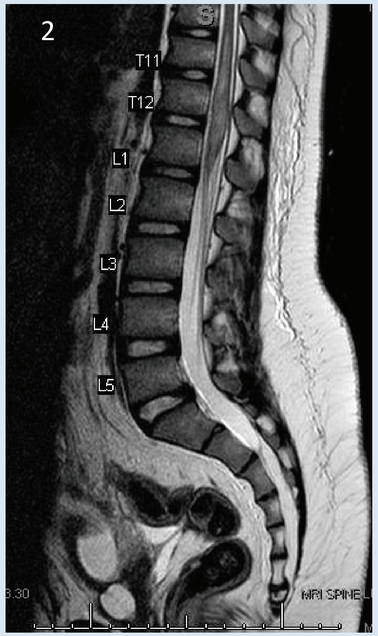

Figure 2 (above): T2-weighted sagittal MRI demonstrating hyperintense edema-like signal extending within the spinal cord from T10-T11 to the conus.

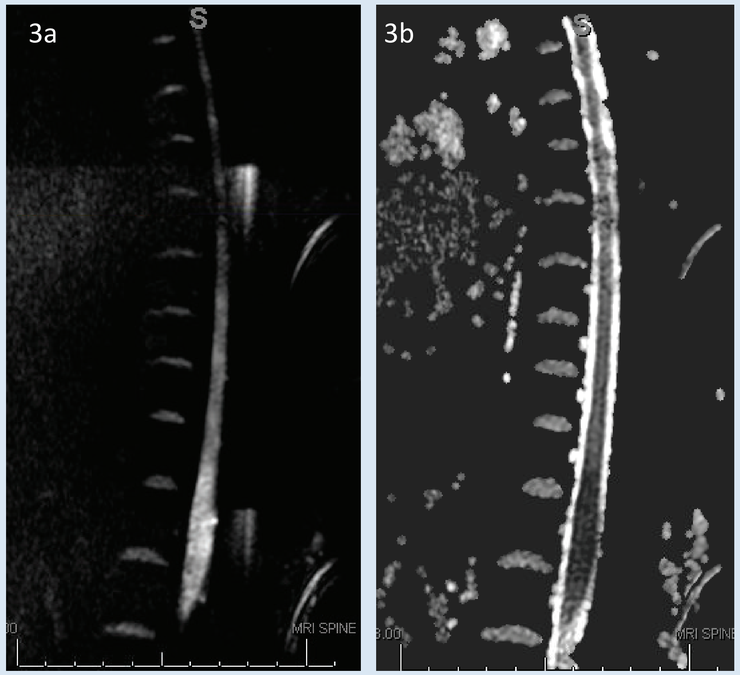

Figure 3: DWI (3a) and ADC (3b) sequence of MRI spinal cord demonstrating diffusion restriction with ADC correlate concerning for spinal cord infarction

Examination

Patient was alert and oriented with intact cranial nerve function. Upper extremity strength and sensation were normal. There was 0/5 strength throughout bilateral lower extremities with absent patellar and achilles deep tendon reflexes. He had impaired vibration, proprioception, and temperature sensation up to about L1 sensory level bilaterally.

Results

MRI lumbar spine revealed a transverse spinal cord infarct extending from T10 to the conus medullaris. Thoracoabdominal CT angiogram was negative for obvious aortic pathology. Hypercoagulable workup was unremarkable. Aspirin 81 mg daily was initiated for secondary prophylaxis. Unfortunately, the patient remains with dense lower extremity paraplegia and sensory loss.

Conclusions

Spinal cord infarction has been a reported complication of lumbosacral nerve blocks in adult literature. We cannot definitively conclude that the cause of this transverse spinal cord infarct was due to placement of the lumbar epidural catheter however, this appears to be the most likely etiology.

Disclosures

The authors do not have anything to disclose.