

Rationale

The development of abnormal involuntary movements is infrequent and an under-reported side effect of certain anti-epileptic drugs (AED). Potential pathologic mechanisms vary with the responsible AED and for the most part are unknown. This study describes two patients who developed hyperkinetic movements shortly after the addition of a first generation AED in an adult and a newer generation AED in a child.

Background

Phenytoin has been rarely implicated in the development of involuntary movements. A variety of movements have been described ranging from tremors to choreo-athetoid movements. Different pathogenic mechanisms have been proposed. The widely accepted theory is that dopamine metabolism and levels of dopamine metabolites in CSF are affected, hence, causing abnormal movements similar to those induced by neuroleptics.

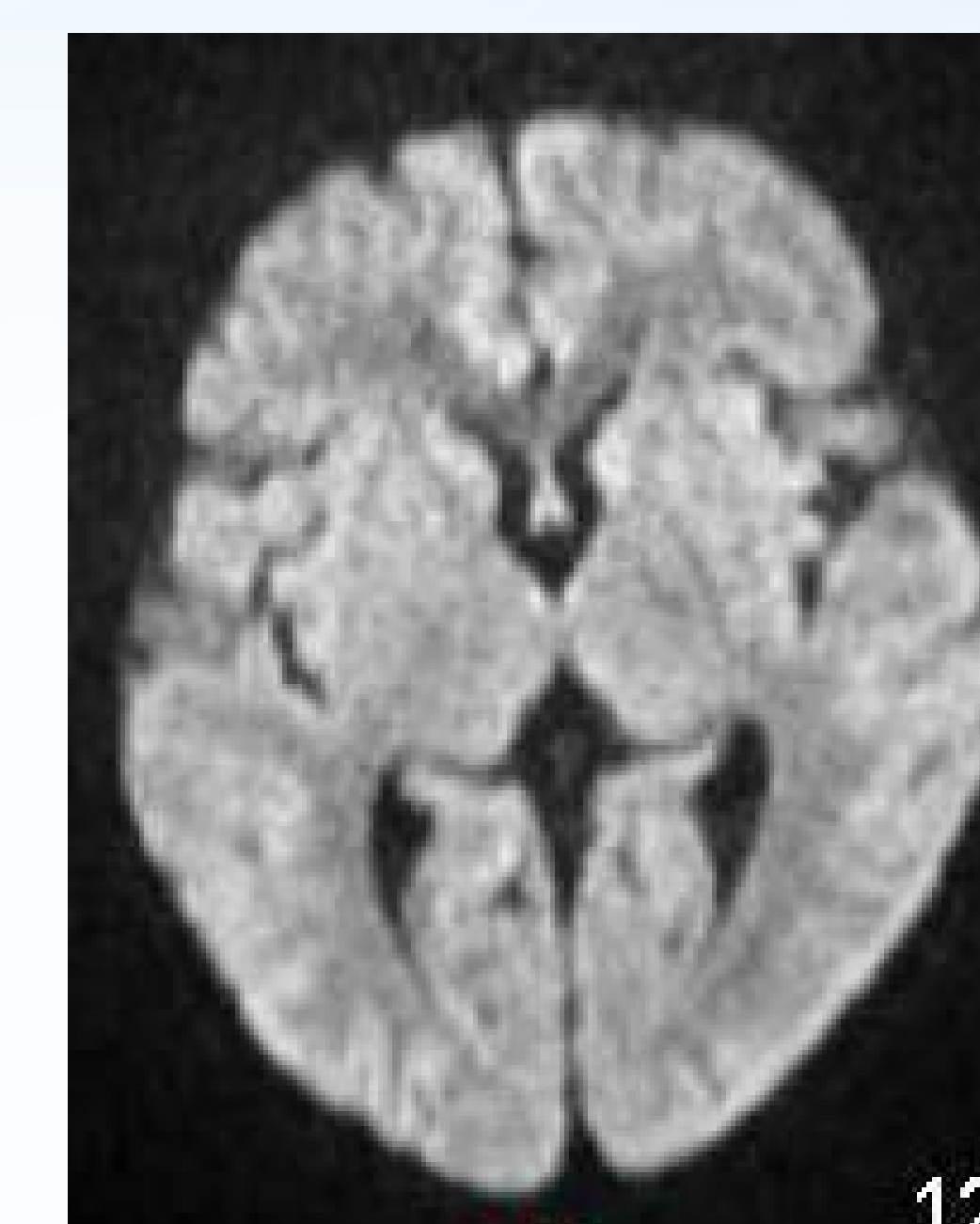
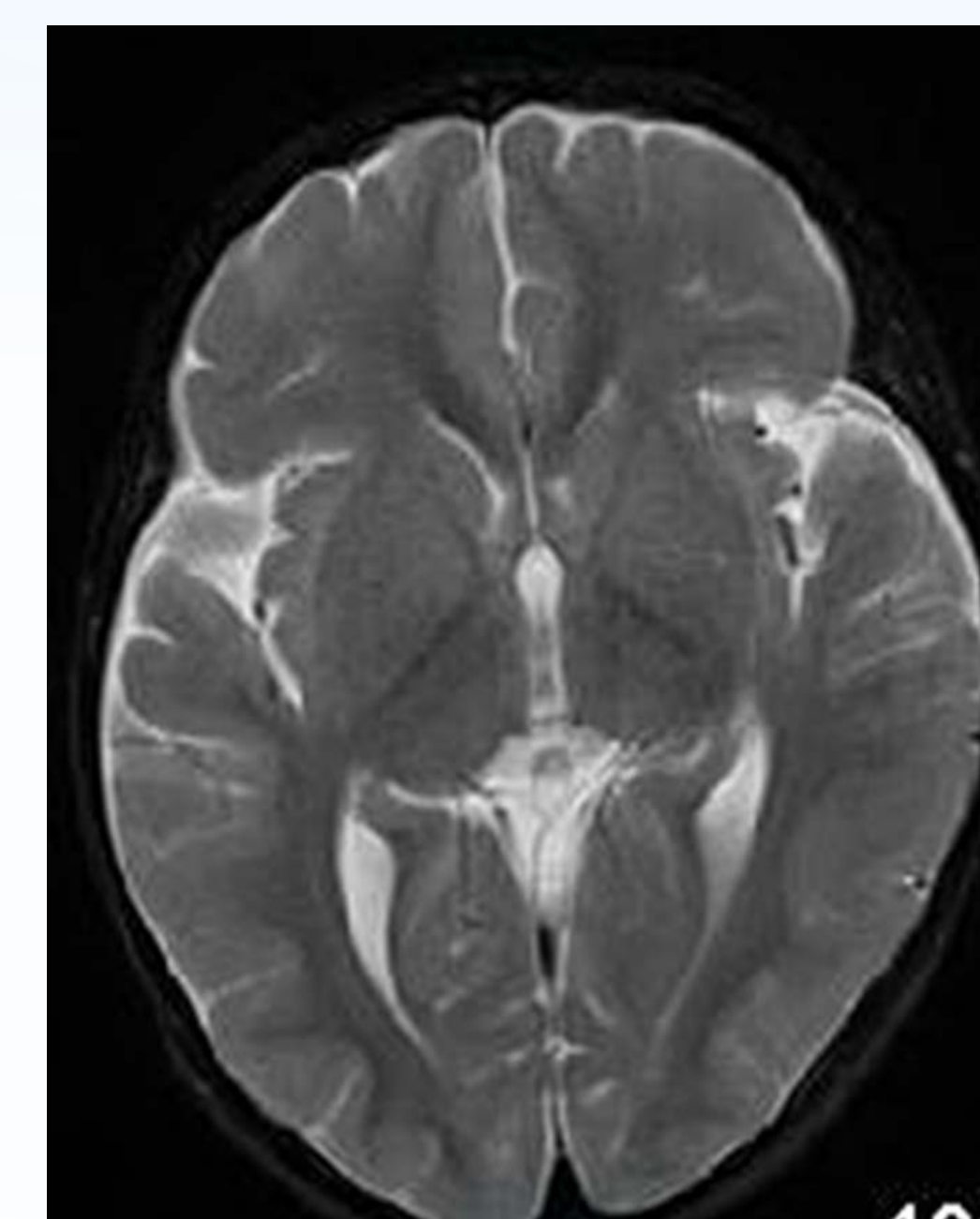
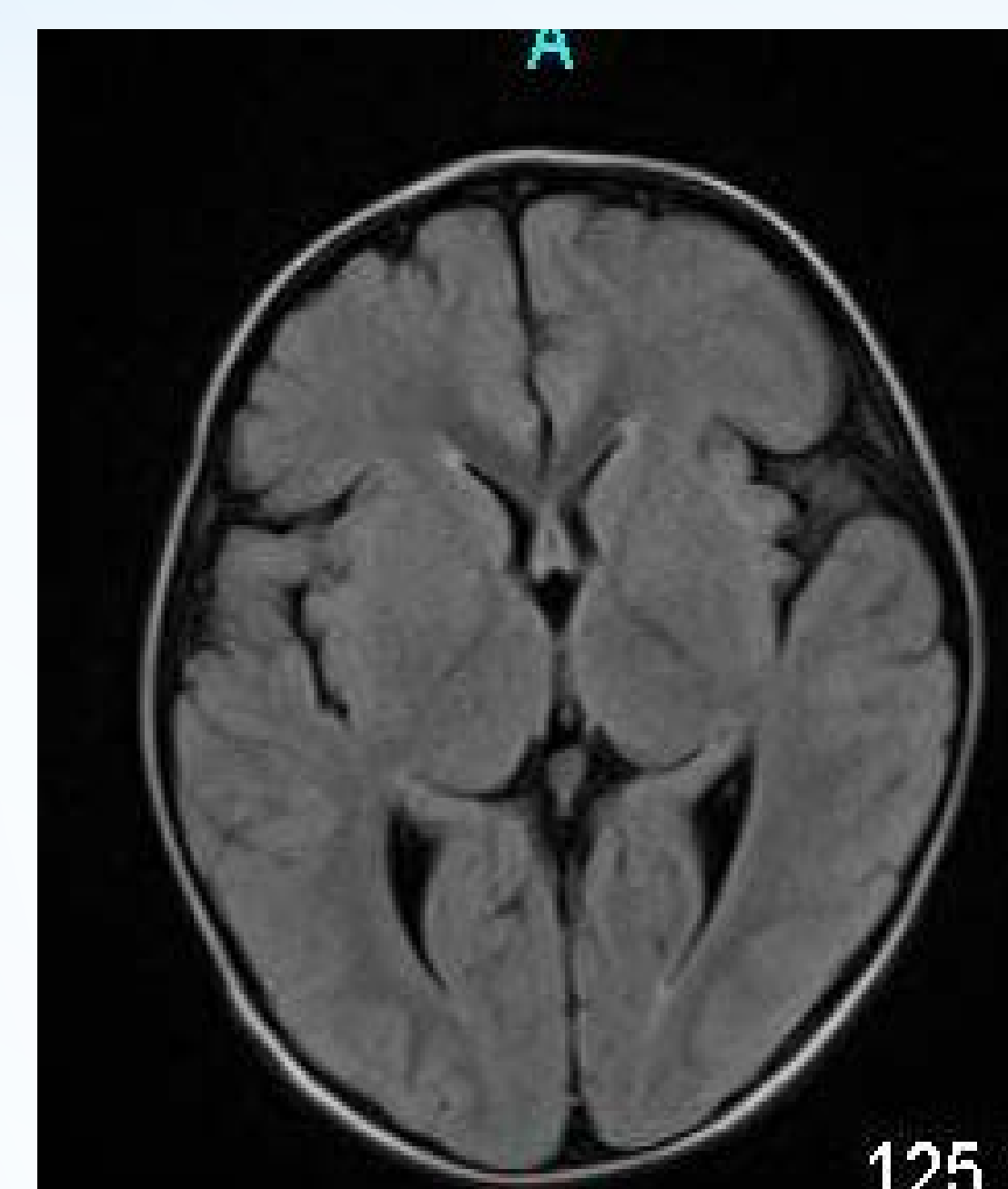
Since the licensing of vigabatrin, over 50 cases of abnormal movements have been reported as per MHRA 2009 report.

Case 1

A 68 year old gentleman, with 15 year history of Parkinson's Disease (PD) and on a stable regimen of Carbidopa/Levodopa, experienced multiple focal seizures, which prompted initiation of levetiracetam. Later continuous video-EEG monitoring revealed subclinical seizures which lead to the addition of phenytoin with subsequent resolution of the seizures. No changes were made in his PD medications. Within 3 days of monitoring, he developed repetitive facial grimacing, dystonic oral puckering, blepharospasm and right upper extremity dystonia, none of which had an EEG correlate. The patient's movements subsided within a week after discontinuation of phenytoin.

Case 2

A 3 year-old boy with Down Syndrome and history of infantile spasms had exhausted his vigabatrin supply and was managed with clonazepam for two weeks prior to presentation. Vigabatrin was restarted and within 24 hours, the child began having abnormal movements characterized as generalized chorea, lip smacking, blepharospasm, and facial spasms. An MRI of the brain was negative for any structural or new lesions (MRI samples pictured below). Continuous video-EEG monitoring did not demonstrate any ictal discharges concomitant to the patient's movements. The child was weaned off vigabatrin. Although there has been improvement in his movements, these persisted to some extent at his 4 months follow up visit.



Discussion

Development of abnormal movements with AEDs has been reported, mostly in patients with underlying CNS disorder. These can develop regardless of drug level and are mostly reversible. Rarely residual movements can persist despite discontinuation of AED.

MRI abnormalities in basal ganglia, thalamus and cerebellum, with and without movements have been reported in patients taking vigabatrin. However due to lack of definitive evidence and prospective comparative data, MRI changes and movement disorders are considered to be independent risks with vigabatrin use.

Conclusion

These two cases suggest that patients with underlying CNS pathology are prone to developing AED associated abnormal movements. This type of side effect can increase healthcare utilization. Treating physicians should be aware of this potential consequence when starting certain AED. Educating patients and caregivers can facilitate early detection and reporting of drug-induced abnormal movements.

References

- 1 - Harrison MB et al. Phenytoin and dyskinesia: a report of two cases and review of the literature. *Move Disord.* 1993;8(1):19-27
- 2 - Dill P et al. Are vigabatrin induced T2 hyperintensities in cranial MRI associated with acute encephalopathy and extrapyramidal symptoms? *Eur J Paediatr Neurol.* 2013;17(3):311-5
- 3 - Pearl PL et al. Cerebral MRI abnormalities associated with vigabatrin therapy. *Epilepsia* 2009;50(2):184-94