Progressive Multifocal Leukoencephalopathy in Acquired Immunodeficiency Syndrome with high T-Helper Cell Count: Report of Two Cases.

Yousef Hannawi, M.D.[1], Shirine Majmudar, M.D.[1], Jharna Shah, M.D., MPH[1], Peter W. Johnson[2], Clay Goodman, M.D.[2,3], Joseph S. Kass, M.D.[1]

[1] Department of Neurology, [2] Office of Student Affairs, [3] Department of Pathology and Immunology, Baylor College of Medicine, Houston, TX.

Objective:
To report two cases of Progressive Multifocal Leukoencephalopathy (PML) associated with Acquired Immunodeficiency Syndrome (AIDS) and elevated CD4 count, atypical clinical presentations and radiographic features.

Case 1:
Clinical presentation:
- 46 year-old man with AIDS (CD4: 420 cells/mm3, viral load< 48 copies/ml) presented with a 3-month history of generalized weakness, fatigue, dysarthria and dysphagia for solids and liquids.
- His weakness started in the right lower extremity and progressed to quadriparesis.

Neurological examination:
- Spastic dysarthria and pseudobulbar affect with intermittent crying.
- Cranial nerve examination revealed only tongue fibrillation.
- Motor examination: Diffuse atrophy & weakness, distally more than proximally and on the right side more than left side.
- He was hyperreflexic with clonus in the lower extremities.
- He had mild dysmetria in the upper extremities bilaterally.

Radiologic findings:
- MRI brain w/wo contrast: bilateral T2 hyperintensities involving the corticospinal tracts from the level of internal capsule to brainstem.
- MRI of the C-spine w/wo contrast showed right sided myelomalacia at the level of C3-C7.

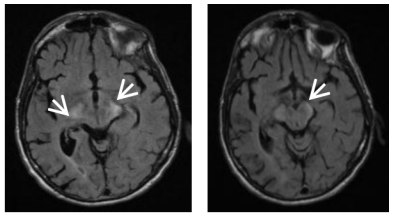

MRI of the brain showing T2 prolongation of the corticospinal tracts bilaterally

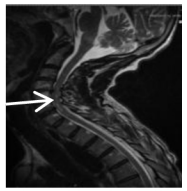

MRI of the cervical spine showing myelomalacia from C3 level to C7 level.

Laboratory data:
- CSF: WBC 6 cells/mm3 (94% lymphocyte), protein 110 mg/dl. CSF HSV-1, HSV-2, EBV, CMV were negative. CSF JCV DNA PCR was positive.

Hospital course:
- PEG tube placement for severe dysphagia.
- Complicated by respiratory failure secondary to aspiration pneumonia requiring intubation.
- Patient's code status was changed to comfort care and he died of respiratory failure.
- Autopsy showed diffuse cerebral hemispheres and brain stem demyelination with classic pleomorphic multinucleated astrocytes and ground glass appearance of infected oligodendrocyte nuclei consistent with PML.

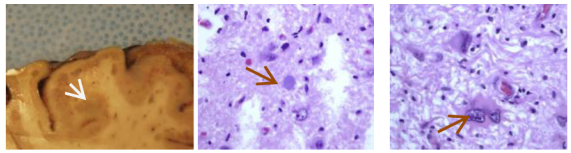

Brain autopsy showing from left to right: patchy subcortical demyelination on gross examination, ground glass appearance of the infected oligodendrocyte nucleus and pleomorphic multinucleated astrocyte on H&E.

Case 2:
Clinical presentation:
- 50 year-old female with AIDS (CD4: 513 cells/mm3, viral load: 284,000 copies/ml) with a 3-week history of gait instability that began with dragging of right lower extremity.
- She also complained of confusion, dysarthria, decreased appetite and thirty-pound weight loss over a month period.

Neurological examination:
- Ataxic dysarthria, impaired ocular smooth pursuits and saccades, bilateral limb dysmetria and titubation. She was hyperreflexic in the lower extremities bilaterally.

Radiologic findings:
- MRI Brain : Nonenhancing T2 hyperintensity in the brachium pontis and cerebellar hemispheres.

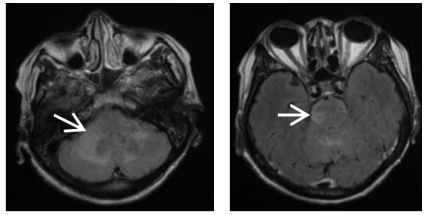

Brain MRI: T2 hyperintensity in the brainstem and cerebellum

Laboratory data and Hospital Course:
- CSF: WBC 97 cells/mm3 (lymphocyte-predominant), protein 94.6 mg/dl. Cryptococcus antigen, West Nile virus PCR neg. JCV DNA PCR positive.
- She was initiated on HAART and was stable at three-month follow up.

Discussion:
- PML is typically associated with low CD4 count in patients with AIDS (CD4<200). The highest CD4 count that has been reported is > 700. Both of our patients had high CD4 counts (420 and 513, respectively).
- The typical clinical presentation for PML is focal neurological symptoms. In contrast, both of our patients had atypical findings- predominantly upper motor neuron findings (as seen in PLS or ALS) and pancerebellar syndrome (as seen in paraneopalastic cerebellar degeneration.)
- Typical MRI findings include T2 hyperintensities involving the parietal or occipital lobes. Our patients had atypical involvement of the corticospinal tracts and brain stem and cerebellar involvement.
- The gold standard for diagnosis is brain biopsy which shows bizarre astrocytes, enlarged oligodendrocyte nuclei and demyelination which were seen on the autopsy of the first case. The diagnosis in the second case was made based on the MRI, CSF JCV DNA PCR and absence of alternative explanation.
- Treatment of PML in AIDS involves initiation of antiretroviral therapy. There are no specific therapies.

Conclusion:
- PML may present in patients with elevated CD4 counts. These patients may have variable clinical and radiographic presentations.

References:
1. Berger J. The Clinical Features of PML. Cleveland Clinic Journal of Medicine (2011 Nov) 78; Supp 2: S8-S12.
2. Mascarello M. PML in an HIV patient receiving successful long-term HAART. J Neurovirol. (2011) 17(2): 196-199.

Disclosure: This data has been presented at the Current Neurology Conference, Baylor College of Medicine, Houston, TX, November, 2012.