Improvement in Cortical Myoclonus in a Patient with VIM Deep Brain Stimulation for Essential Tremor

Melissa Kagnoff, M.D., M.P.H.; Joohi Jiminez-Shahed, M.D.

Parkinson's Disease Center and Movement Disorders Clinic, Department of Neurology, Baylor College of Medicine, Houston, Texas

BACKGROUND

- Myoclonus is sudden, brief, involuntary jerking caused by abrupt muscle contraction or discontinuation of ongoing muscular activity (negative myoclonus).[1]
- Classification is clinical, physiologic and/or anatomical.[2]
- Cortical myoclonus is the most common type. Its pathophysiology is incompletely understood, though there may be cerebellar influences on cortical excitability.[1]
  - Examples include posthypoxic syndrome,[2] Lance Adams syndrome, uremia[1] and chronic renal failure.[5]
- Mechanism(s) specific to metabolic myoclonus are largely unexamined.
- Case reports have described improvement in anoxic/hypoxic myoclonus, considered cortical, after pallidal and thalamic deep brain stimulation (DBS).[3,4]

METHODS

- We describe a case of improved cortical myoclonus of multifactorial origin with DBS of the ventral intermediate nucleus (VIM) of the thalamus, placed for treatment of essential tremor (ET).
- ON/OFF assessments using grading from the Unified Rating Scale (UMRS) were performed.

CASE REPORT

- An 85-year old right-handed man with CAD, CHF, OSA, COPD and childhood-onset essential tremor (ET) was treated with left VIM DBS in 2003 for medically refractory tremor.
- He presented for evaluation after developing disabling jerking movements in all extremities.
- Symptom onset: 1 week after 2 hospital admissions for acute on chronic renal failure and worsening hypercapnia.
  - During hospitalization, K+ = 7. Creatinine = 4.6 (baseline 2.5), and pCO2 = 56.
  - He underwent temporary transvenous pacemaker placement, placed on BIPAP and given insulin, glucose and kayexalate.
  - On discharge 5 days later, K+ = 5.8, BUN = 52, creatinine = 2.4.
  - Neurontin 600 mg BID was resumed for mood.
- Involuntary, non-bothersome jerking movements in all limbs began during the second hospitalization
- 1 week after discharge, he fell upon standing secondary to severe uncontrollable jerking of his legs.
- Since then, jerking persisted which prevented safe ambulation and activities of daily living.
- He presented to clinic in a wheelchair with marked myoclonus and tremor.
- The DBS was found to be off.

RESULTS

- Left ViM DBS settings were: polarity: 0(-) 1(+); amplitude: 3.7V; pulse width: 150 µsec; frequency: 185 Hz.
- Components of the UMRS were scored. (Table 1)
- The maximum possible myoclonus rating was 76, and myoclonus improved by 14.5% with DBS ON. (Video 2)
- The maximum lateralized score was 32 (Figure 3)

RESULTS cont'd

- Prominent negative myoclonus was noted OFF DBS with forward posture holding, attempting to pour water and standing, resulting in falls. All improved markedly with DBS ON.
- Tremor Research Group (TRG) scales OFF and ON were 31.5 and 16.5 (Figure 2)
- Myoclonus was not observed in clinic 5 months prior. (Video 1)

Table 1: Myoclonus Ratings based on Unified Myoclonus Rating Scale (UMRS)

TASK	Left ViM DBS OFF	Left ViM DBS ON
Rest		
Right	Frequency 4 Amplitude 2	Frequency 4 Amplitude 2
Left	Frequency 4 Amplitude 2	Frequency 4 Amplitude 2
Tongue protrusion	Frequency 4 Amplitude 2	Frequency 3 Amplitude 2
Forward postural position		
Right	Frequency 4 Amplitude 4	Frequency 3 Amplitude 2
Left	Frequency 3 Amplitude 3	Frequency 3 Amplitude 3
Lateral postural position		
Right	Frequency 3 Amplitude 4	Frequency 3 Amplitude 3
Left	Frequency 3 Amplitude 2	Frequency 3 Amplitude 2
Stand	3	1
Spirals		
Right	3	1
Left	3	3
Pour water		
Right	3	1
Left	3	3
TOTAL MYOCLONUS RATINGS	59	48

Frequency ratings:
0 = no jerks
1 = ≤1 jerk per 10 seconds
2 = 2-3 jerks per 10 seconds
3 = 4-9 jerks per 10 seconds
4 = ≥10 jerks per 10 seconds

Amplitude ratings:
0 = 0
1 = trace movement only
2 = small-amplitude jerks, easily visible (<25% of possible maximum movement)
3 = moderate-amplitude jerks (25-75% of possible maximum movement)
4 = large-amplitude jerks (near maximum movement)

For standing, amplitude:
0 = no jerks
1 = trace movements, does not interfere with standing
2 = small amplitude jerks, mildly interferes with standing
3 = moderate-amplitude jerks, definitely interferes with ability to stand without assistance
4 = large amplitude jerks prevent standing

Spiral ratings:
0 = normal
1 = completes the spiral but crosses the lines ≤2 times
2 = completes the spiral but crosses the lines 3-10 times
3 = completes the spiral but crosses the lines >10times
4 = cannot complete the spiral, or cannot hold the pen or keep it on the paper

Pouring water:
0 = normal, no spill
1 = clumsy but does not spill
2 = spills less than half the water
3 = spills at least half the water
4 = cannot hold the glass or refuses to try secondary to fear of spilling water

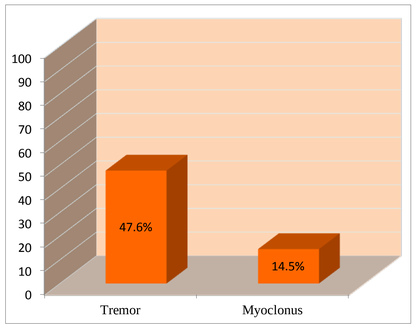

Figure 2: Overall % reduction of tremor and myoclonus with L ViM DBS ON.

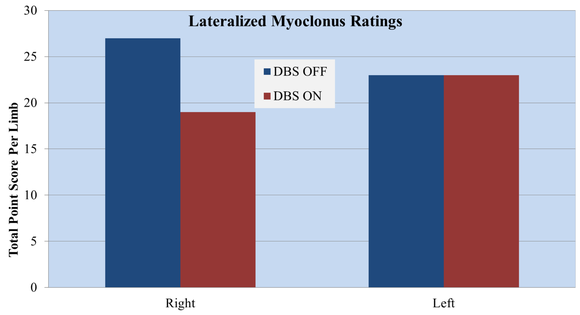

Figure 3. L Vim DBS improves myoclonus in both limbs: 25% reduction in the right limbs, 0% reduction in the left limbs.

DISCUSSION

- Our patient's presentation is most consistent with cortical myoclonus based on: sudden multi-focal jerking limb movements worse with action, multiple metabolic abnormalities and history of high-dose gabapentin exposure.
- Negative myoclonus may be caused by activation of inhibitory areas within sensorimotor cortex.[1]
- Metabolic myoclonus is typically cortical.

DISCUSSION cont'd

- Case reports have described improvement in action myoclonus from perinatal anoxic injury after ViM DBS[3] and in adult LAS after pallidal DBS.[4]
- ViM and pallidal DBS are reported to improve subcortical myoclonus, in myoclonus-dystonia.[6,7]
- To our knowledge, this is the first case to demonstrate improvement in cortical non-anoxic myoclonus with ViM DBS.

- The ViM receives cerebellar input and sends projections to the primary motor cortex (M1).
- ViM DBS likely improves tremor by modulating cerebello-thalamo-cortical connection loops.[8]
- In ET and PD, thalamic firing patterns are aberrant[9] and high frequency DBS may "normalize" thalamocortical connectivity.

- Oscillatory EEG potentials using jerk-locked averaging in motor cortex precede cortical positive and negative myoclonus.[10]
- Hanajima et al (2011) facilitated conditioned motor evoked potentials in cortical myoclonus after transcranial magnetic stimulation to M1.
- Cerebellar changes and pathology are associated with cortical excitability and myoclonus.[1]
- These findings suggest:
  - Cortical myoclonus results from abnormal rhythmic activity of M1.
  - ViM DBS may improve cortical myoclonus by suppressing this activity via enhanced thalamic inhibition.

CONCLUSIONS

- Simultaneous improvement of tremor and cortical myoclonus with ViM DBS:
  - confirms prior findings of ViM connectivity to the primary motor cortex
  - illustrates ViM stimulation can regulate involuntary motor activity whether the primary site of abnormal neuronal activity is in the thalamus or downstream in the cortex.
  - suggests that the same neural networks underlying ET are implicated in cortical myoclonus.
- Further studies delineating the neuronal connectivity and related electrophysiology of myoclonus and tremor are warranted.

REFERENCES

1. Shibasaki H, Thompson PD. Milestones in Myoclonus. Mov Disord 2011; 26:1142-1148.
2. Caviness JN. Pathophsiology and treatment of myoclonus. Neurol Clin 2009; 27:757-777, vii.
3. Kobayashi K, Katayama Y, Otaka T, et al. Thalamic deep brain stimulation for the treatment of action myoclonus cause by perinatal anoxia. Stereotact Funct Neurosurg 2010; 88:259-263.
4. Yamada K, Tomotaka S, Naohiro S, Jun-ichi K. GPi Pallidal Stimulation For Lance-Adams Syndrome. Neurology 2011; 76:1270-1272.
5. Artieda J, Muruzabal J, Larumbe R, et al. Cortical mechanisms mediating asterixis. Mov Disord 1992; 7:209-216.
6. Rughani A , Lozano A. Surgical Treatment of Myoclonus Dystonia Syndrome. Mov Disord 2013:1-5.
7. Li JY, Cunic DI, Paradiso G, et al. Electrophysiological features of myoclonus-dystonia. Mov Disord 2008;23:2055-2061.
8. Klein JC, Barbe MT, Seifried C, et al. The tremor network targeted by successful VIM deep brain stimulation in humans. Neurology 2012; 78:787-795.
9. Molnar GF, Pilliar A, Lozano AM, Dostrovsky JO. Differences in neuronal firing rates in pallidal and cerebellar receiving areas of thalamus in patients with Parkinson's disease, essential tremor, and pain. Neurology 2005; 93:3094-3101.
10. Ugawa Y, Hanajima R, Kanasawa I. Exaggerated 16-2hz motor cortical oscillation in patients with positive or negative myoclonus. Clin Neurophysiol 2003;114:1278-1284.
11. Hanajima R, Terao Y, Nakatani-Enomoto S, et al. Triad stimulation frequency for cortical facilitation in cortical myoclonus. Mov Disord 2011; 26:685-690.

Poster available for download.