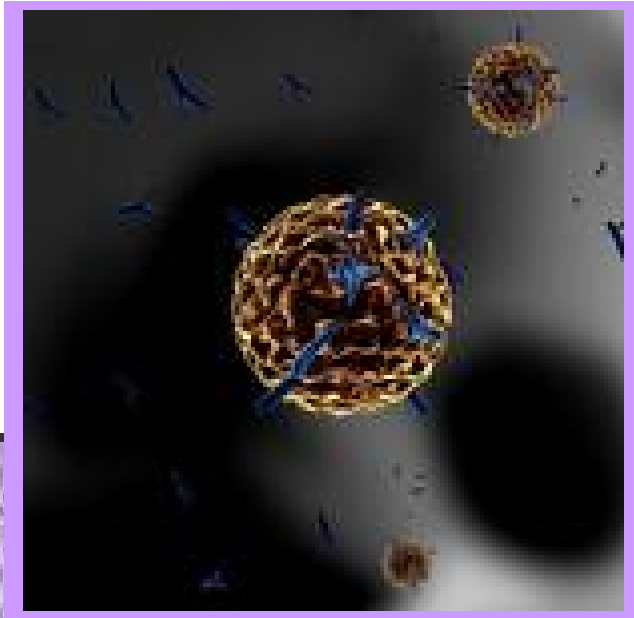
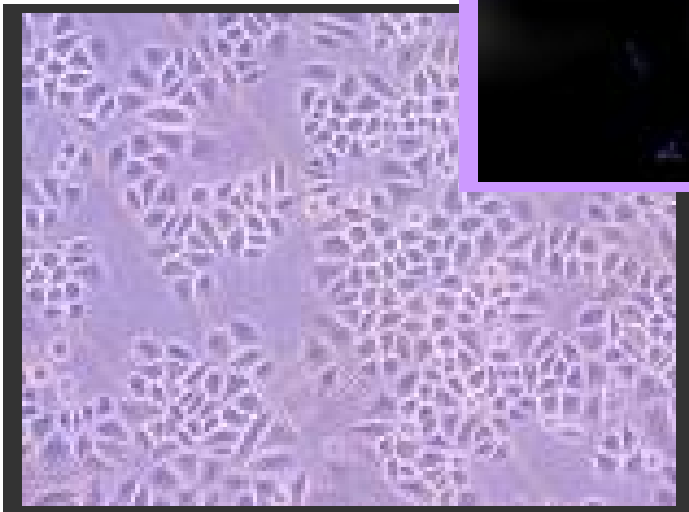


Grand Rounds

Desmoplastic Small Round Cell Tumor: An In-Depth Look

Todd M. LeLeux, M.D.



**Tuesday, May 01, 2007
12:00 PM
BCM Cullen, 201A**

BCM Baylor
College
of Medicine®

Baylor College of Medicine
Department of Pathology

www.bcm.edu/pathology/announcements