DIFUSSE WHITE MATTER ABNORMALITIES AND NEUROLOGIC MANIFESTATIONS IN A PATIENT WITH ANTI-RO POSITIVE ANTIBODIES. CASE REPORT.

Liliana Robles MD[1], Leopoldo Dealvare MD[2], Pilar Guillermo Prieto MD[1], George J. Hutton MD[1], Victor M. Rivera MD[1]
[1]Baylor College of Medicine, Department of Neurology; [2]Neurological Associates of LA

MAXINE MESINGER MULTIPLE SCLEROSIS COMPREHENSIVE CARE CENTER

INTRODUCTION

Anti-Ro (SS-A) antibodies are found in 70% to 97% of patients with primary Sjögren syndrome (pSS) and in 10% to 60% of patients with systemic lupus erythematosus (SLE). Patients with secondary Sjögren associated to rheumatoid arthritis may present with SS-A antibodies in up to 10% to 15% of the cases.

Anti-Ro positivity in pSS has been correlated with severe, progressive and large CNS lesions but the role of isolated anti-Ro (SS-A) antibodies in severe multifocal demyelination in absence of rheumatologic conditions is undetermined.

We describe the case of a 32 year old male with anti-Ro antibodies and severe CNS MRI abnormalities without criteria for systemic lupus erythematosus (SLE), primary Sjögren syndrome (pSS) or rheumatoid arthritis. Other demyelinating diseases and leukodystrophies were investigated.

CASE REPORT

A 32 year old man with history of meningitis at 9 months of age without sequelae and one episode of transverse myelitis 10 years ago from which he completely recovered, presented with new neurologic symptoms in 2008.

During the 1999 evaluation, brain MRI showed diffuse signal abnormalities predominantly in the subcortical white matter of both cerebral hemispheres with no contrast enhancement. (Fig. 1 and Fig. 2) The spinal MRI demonstrated high signal on T2 sequences extending from C4-T1. (Fig. 3) He was treated with IVMP and oral taper of prednisone. No definite diagnosis was established.

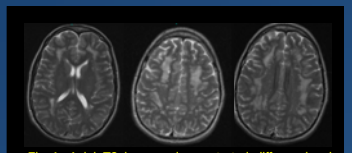

Fig 1. Axial T2 images demonstrated diffuse signal abnormality in the white matter of both cerebral hemispheres. September 1999.

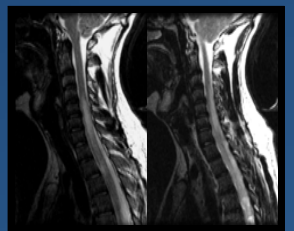

Fig 3. Sagital FSE (fast spin echo) T2 images demonstrate a longitudinal hyperintense lesion extending from C4-T1 levels. September 1999.

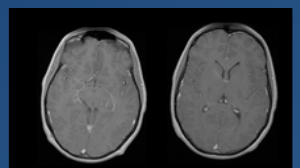

Fig 2. Axial T1 images post-contrast injection. No enhancing lesions are demonstrated. September 1999.

He remained asymptomatic until June 2008 when he presented with sudden onset of dysarthria, anomia and right sided weakness involving face arm and leg.

MRI of brain demonstrated extensive T2 periventricular white matter abnormalities with areas of contrast enhancement in the left frontal lobe and right parietal lobe on T1 sequence. (Fig. 4 and Fig. 5) No hypointensities were evident on T1 axial images. (Fig. 6) Cord lesions were appreciated on MRI at C5-C6, C7-T1 and below T5 level (Fig. 7 and Fig. 8)

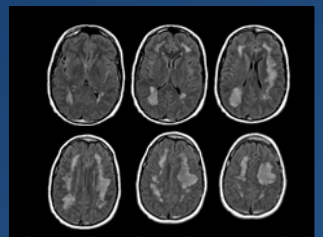

Fig. 4. Axial FLAIR images demonstrate T2 signal in the subcortical and periventricular white matter in the fontal and parietal lobes. July 2008.

Fig. 5. Axial, Coronal and Sagital MRI T1 post-contrast infusion images show enhancement of the left frontal and parietal lobes. July 2008.

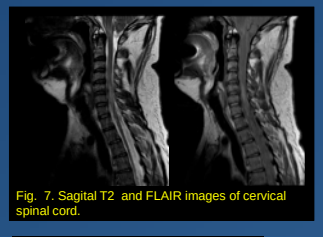

Fig. 7. Sagital T2 and FLAIR images of cervical spinal cord.

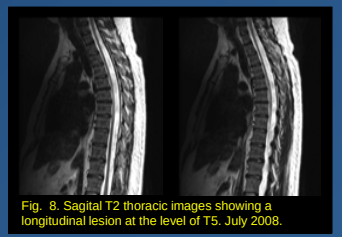

Fig. 8. Sagital T2 thoracic images showing a longitudinal lesion at the level of T5. July 2008.

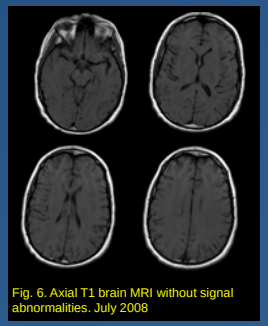

Fig. 6. Axial T1 brain MRI without signal abnormalities. July 2008

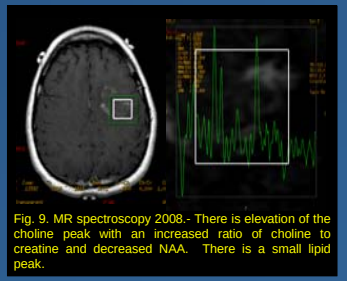

Fig. 9. MR spectroscopy 2008.- There is elevation of the choline peak with an increased ratio of choline to creatine and decreased NAA. There is a small lipid peak.

CSF analysis revealed a normal IgG index (0.65) and no OCB were seen. CSF viral panel was negative. ANA, pANCA, cANCA returned negative. ACE levels, chest and abdominal CT, CEA and CA-125 were normal.

The patient was treated with a cycle of IVMP and oral tapering steroid dose for one week with partial recovery. One week after last steroid dose, the symptoms worsened and he was placed on 3 doses of IVIG without improvement.

Further testing included normal results for VEP, BAEP and SSEP, negative serum NMO antibody and normal serum VLCFA levels. The MRI spectroscopy was consistent with demyelination. (Fig. 9) Anti-Ro antibody returned positive. Follow up MR images continued to show significant post-contrast enhancement. (Fig. 10)

He was placed on oral immunosuppresive treatment (azathioprine) and continues follow up.

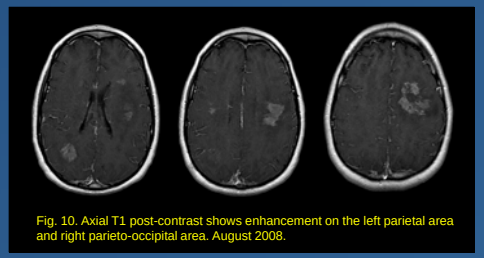

Fig. 10. Axial T1 post-contrast shows enhancement on the left parietal area and right parieto-occipital area. August 2008.

CONCLUSIONS

The anti-Ro antibody detects an intracellular RNA-protein complex. It is primarily found in patients with SLE and Sjögren syndrome. This autoantibody is described to have a 54% sensitivity and 82% specificity in pSS and only 0.1% to 0.5% of control samples have tested positive.

Approximately 25% of patients with positive SS-A antibodies and undifferentiated connective tissue disease will evolve into a definite disorder. Neurologic involvement occurs in 20% of the patients with pSS and was present prior to diagnosis in 81% of the patients in a small case series.

Anti-Ro positivity in pSS has been correlated with severe, progressive and large CNS lesions. Yet the role of anti-Ro antibodies in CNS involvement in the absence of clinical and laboratory data of connective tissue disease is undetermined.

1.Alexander E. Neurologic Disease in Sjogren's syndrome: Mononuclear Inflammatory Vasculopathy Affecting Central/Peripheral Nervous System and Muscle. Rheum Dis Clin of North Am 19:869, 1993.
2.Alexander E., Ranzebach M., Kumar A.J, Kozachuk W.E., Rosenbaum A.E., Patronas N., Harley J.B., Reichlin M. Anti-Ro (SS-A) autoantibodies in central nervous system disease associated with Sjogren's syndrome. Neurology 44:899, 1994.
3.Delalande S., de Seze J., Fauchais A. Hachulla E. Stojkovic T., Ferriby D., Dubucquoi S., Pruvo J., Vermersh P., Hatron P. Neurologic manifestations in primary Sjogren Syndrome. A study of 82 patients. Med 83:280, 2004.
4.Cavazzana I., Franceschini F., Belfiore N., Quinzanini M., Caporali R., Calvazara-Pinton P., Bettoni L., Brucato A., Cattaneo R., Montecucco C. Undifferentiated connective tissue disease with antibodies to Ro/SSa: clinical features and follow-up of 148 patients. Clin Exp Rheumatol 19:403, 2001.
5.Lyons R., Narain S., Nichols C., Minoru S., Reeves W. Effective use of autoantibody tests in the diagnosis of systemic autoimmune disease. Ann. N.Y. Acad. Sci. 1050:217, 2005.
6.Moutsopoulos H.M., Sarmas J.H., Talal N. Is central nervous system involvemement a systemic manifestation of primary sjogren syndrome?. Rheum Dis Clin of North Am 19:909, 2004.