

CLINICAL PRACTICE

Plantar Fasciitis

Rachelle Buchbinder, M.B., B.S., F.R.A.C.P.

This Journal feature begins with a case vignette highlighting a common clinical problem. Evidence supporting various strategies is then presented, followed by a review of formal guidelines, when they exist. The article ends with the author's clinical recommendations.

A 55-year-old overweight woman presents with a three-month history of pain in her right inferior heel. The pain is worse on taking her first steps in the morning. The physical examination is normal except for nonspecific tenderness in the region of the medial calcaneal tubercle. How should the patient be evaluated and treated?

THE CLINICAL PROBLEM

EPIDEMIOLOGIC FEATURES

Plantar fasciitis, reportedly the most common cause of pain in the inferior heel, is estimated to account for 11 to 15 percent of all foot symptoms requiring professional care among adults.^{1,2} Reliable population-based incidence data are lacking, although plantar fasciitis has been reported to account for about 10 percent of injuries that occur in connection with running³⁻⁵ and is common among military personnel.⁶ The incidence reportedly peaks in people between the ages of 40 and 60 years in the general population and in younger people among runners.⁷⁻⁹ The predominance of the condition according to sex varies from one study to another.^{5,8,10} The condition is bilateral in up to a third of cases.^{6-8,10}

From the Department of Clinical Epidemiology, Cabrini Hospital; and the Department of Epidemiology and Preventive Medicine, Monash University — both in Melbourne, Vic., Australia. Address reprint requests to Dr. Buchbinder at Cabrini Medical Centre, Suite 41, 183 Wattletree Rd., Malvern, VIC 3144, Australia, or at rachelle.buchbinder@med.monash.edu.au.

N Engl J Med 2004;350:2159-66.

Copyright © 2004 Massachusetts Medical Society.

PATHOLOGICAL FEATURES

The site of abnormality is typically near the site of origin of the plantar fascia at the medial tuberosity of the calcaneus (Fig. 1). Histologic examination of biopsy specimens from patients undergoing plantar fascia–release surgery for chronic symptoms has shown degenerative changes in the plantar fascia, with or without fibroblastic proliferation, and chronic inflammatory changes.¹¹⁻¹³

RISK FACTORS

The cause of plantar fasciitis is poorly understood and is probably multifactorial. Limited data from case–control studies have identified such risk factors as obesity, occupations that require prolonged standing, pes planus (excessive pronation of the foot), reduced ankle dorsiflexion, and inferior calcaneal exostoses (or heel spurs).^{6,9,14-18}

Because of its high incidence among runners, plantar fasciitis is commonly assumed to be caused by repetitive microtrauma.³ Proposed risk factors include running excessively (or suddenly increasing the distance run), wearing faulty running shoes, running on unyielding surfaces, and having a cavus (high-arched) foot or a shortened Achilles tendon, but evidence for most of these factors is limited or absent.¹⁹

CLINICAL COURSE

On the basis of long-term follow-up data in large case series that predominantly involved patients seen in orthopedic practices, the clinical course for most patients with plantar fasciitis is favorable, with resolution of symptoms in more than 80 percent of patients

within 12 months.^{8,20-22} Up to 5 percent of patients in reported case series are treated surgically,^{3,7,8,22} although reliable data on surgical rates in unselected patients are lacking.

STRATEGIES AND EVIDENCE

CLINICAL DIAGNOSIS

The diagnosis of plantar fasciitis can be made with reasonable certainty on the basis of clinical assessment alone. Patients typically report a gradual onset of pain in the inferior heel that is usually worse with their first steps in the morning or after a period of inactivity. Patients may describe limping with the heel off the ground. The pain tends to lessen with gradually increased activity but worsens toward the end of the day with increased duration of weight-bearing activity. Associated paresthesias are uncommon. Patients may report that before the onset of their symptoms, they increased the amount or intensity of their regular walking or running regimen, changed footwear, or exercised on a different surface. There is often a localized area of maximal tenderness over the anteromedial aspect of the inferior heel. Limitation of ankle dorsiflexion due to tightness of the Achilles tendon may be present. Other causes of pain in the inferior heel are usually distinguishable on the basis of history and physical examination (Table 1).^{23,24}

IMAGING

Imaging plays a limited role in routine clinical practice, although it may be useful in selected cases to rule out other causes of heel pain or to establish the diagnosis of plantar fasciitis when it is in doubt. Occasionally, it may be difficult to differentiate plantar fasciitis from calcaneal stress fracture on clinical grounds. Plain radiographs may rule out calcaneal stress fracture and other rare bony lesions. Although the detection of heel spurs is of no value in either confirming the diagnosis of plantar fasciitis or ruling it out, a “fluffy periostitis” with ill-defined borders may suggest an underlying spondyloarthropathy.

When plain radiographs are normal, bone scans are useful for distinguishing plantar fasciitis from calcaneal stress fracture. Positive findings on bone scanning for plantar fasciitis have been reported in 60 to 98 percent of cases,²⁵ although the false positive rate is unknown. Typical findings in the early images include increased blood flow and blood

Figure 1 (facing page). Plantar and Medial Views of the Foot Demonstrating the Origin and Insertion of the Plantar Fascia and the Location of Nerves in Proximity to the Heel.

The windlass mechanism, or bowstring effect, of the plantar fascia refers to its function in raising the arch of the foot during the push-off phase of walking.

pooling; in the delayed images, findings often include a focal increase in activity at the plantar fascial insertion site in the calcaneus. By contrast, a linear fracture line or more diffuse calcaneal uptake on delayed images is consistent with calcaneal stress fractures.

Ultrasonography may be diagnostically useful, although, like other imaging techniques, it is not routinely used. The plantar fascia can be easily distinguished from the hyperechoic superficial heel pad of fat and the underlying calcaneus and is normally 2 to 4 mm thick.²⁶ Many studies have found a marked increase in the thickness of the plantar fascia in plantar fasciitis (to a total of approximately 5 to 7 mm) and have variably demonstrated local or diffuse hypoechogenicity at the calcaneal insertion of the plantar fascia, loss of definition at the interface between the plantar fascia and the surrounding tissue, and peri-insertion edema.^{25,26}

Magnetic resonance imaging can also be used to visualize the plantar fascia, with sagittal and coronal images.²⁷ Normally, the plantar fascia is characterized by homogeneous low signal intensity on all pulse sequences. In plantar fasciitis, a marked increase in plantar fascial thickness can be detected, together with variable features of moderately increased signal density in the substance of the fascia on T₂-weighted and short tau inversion-recovery pulse sequences (consistent with edema and intrasubstance microtears) and abnormally increased signal intensity in adjacent subcutaneous tissue and in the calcaneus at the plantar fascial insertion site. Markedly increased signal intensity in the calcaneus may be suggestive of plantar fasciitis associated with an underlying spondyloarthropathy.²⁸

TREATMENT

A variety of therapies are used for plantar fasciitis; however, there are few data from high-quality, randomized, controlled trials that support the efficacy of these therapies.²⁹ Initiation of conservative treatment within six weeks after the onset of symptoms

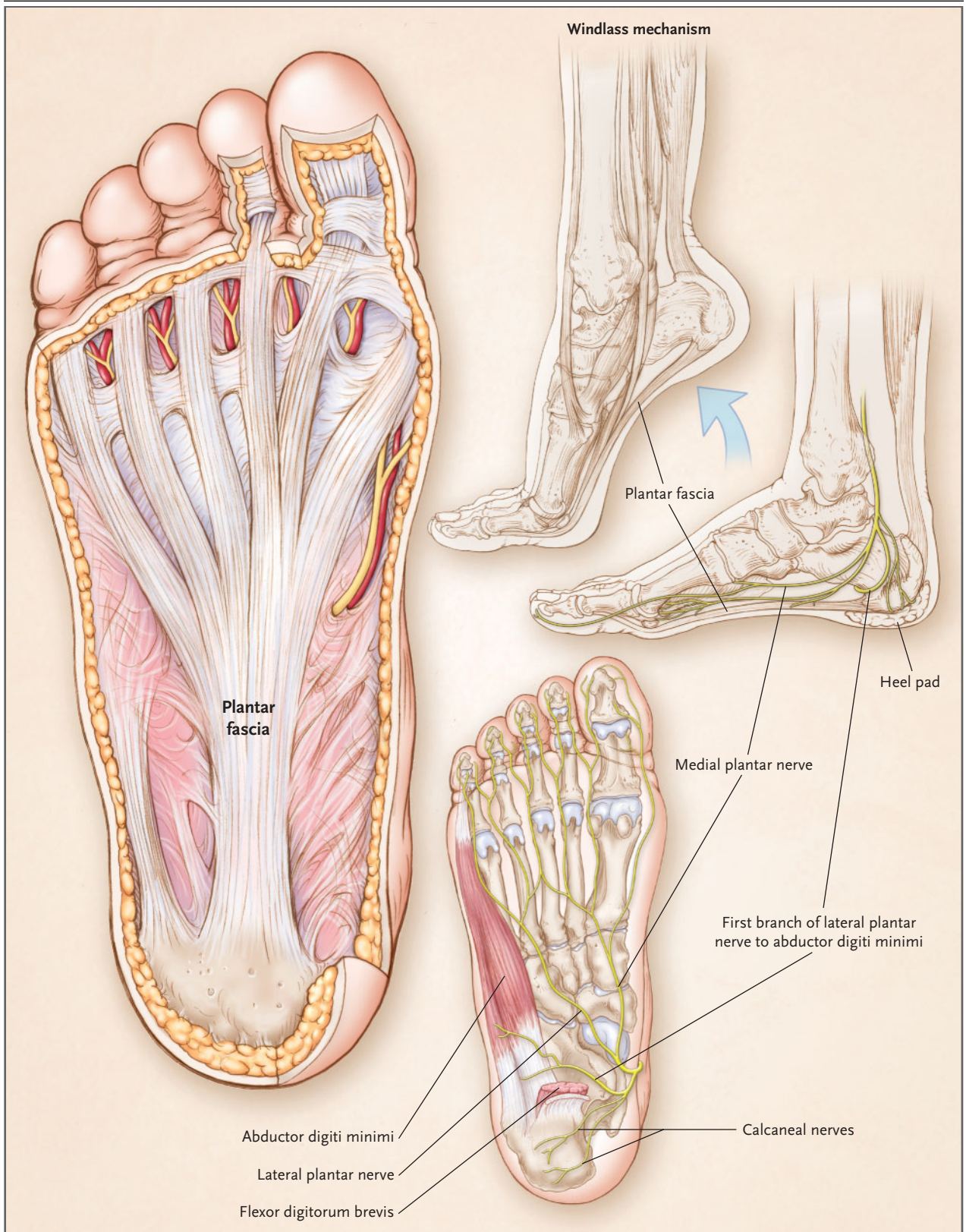


Table 1. Differential Diagnosis of Pain in the Inferior Heel.

Site and Diagnosis	Distinguishing Clinical Features
Plantar fascia	
Plantar fasciitis	Morning pain (typical of both idiopathic plantar fasciitis and fasciitis associated with an underlying spondyloarthropathy, but not usually a feature of other causes of pain in the inferior heel); nocturnal pain should raise suspicions about other conditions, including cancer, infection, and neuropathic pain
Rupture of plantar fascia	Sudden onset of tearing pain and inability to bear weight after physical activity; may be accompanied by bruising or swelling or both, a noticeable decrease in arch height as compared with the other foot, hammer-toe deformities, an inability to spread the toes, and metatarsal stress fractures; in the context of plantar fasciitis, initial symptoms may gradually be replaced by pain and weakness in the longitudinal arch and lateral midfoot; majority of patients recover fully after 6 to 12 months, although persistent pain and flattening of the longitudinal arch have been reported
Enthesopathies	Unilateral or bilateral; bilateral symptoms strongly suggest an underlying spondyloarthropathy (e.g., Reiter's syndrome, ankylosing spondylitis, or psoriatic arthritis); back pain, morning stiffness, inflammatory joint disease, and psoriasis may be present
Bone	
Calcaneal stress fracture	May occur after excessive or repetitive weight-bearing exercise; pain may be vague, made worse by weight bearing, and relieved by rest; tenderness on mediolateral compression of the calcaneus (squeeze test); plain radiographs may show an area of sclerosis, usually from the superior portion of the calcaneus directed obliquely and inferiorly, but may be normal, particularly if obtained soon after the injury
Bone bruise	Generalized pain over the inferior heel after excessive weight-bearing exercise or direct trauma
Infection	Symptoms of infection, such as fever; nocturnal pain
Cancer	Deep bone pain; nocturnal pain
Paget's disease	Bowing of the tibia; bone pain elsewhere in the body; elevated alkaline phosphatase level
Soft tissue	
Fat-pad atrophy	Occurs in the elderly, manifested as pain or tenderness in the central heel that is usually absent on arising in the morning; atrophy of the heel pad
Bursitis	Retrocalcaneal swelling and erythema of the posterior heel
Nerve (nerve-entrapment or compression syndromes)	
Posterior tibial nerve (tarsal tunnel syndrome)	Burning pain (and tenderness) that follows the path of the posterior tibial nerve inferior to the medial malleolus, radiating into the plantar aspect of the foot and toward the toes, suggests tarsal tunnel syndrome; may also radiate proximally up the leg; aggravated by prolonged weight bearing and walking on hard surfaces; reproduction of symptoms with percussion on the medial aspect of the heel (Tinel's test) suggests nerve involvement; may occur in association with plantar fasciitis
Medial calcaneal branch of posterior tibial nerve	Burning pain in the medial and plantar areas
Nerve to abductor digiti quinti	Burning pain in the heel pad
S1 radiculopathy	Pain radiating down the leg to the heel, with absent or reduced ankle reflex and weakness of dorsiflexion of the big toe
Neuropathic pain	Diffuse foot pain; nocturnal pain

is commonly believed to hasten recovery from plantar fasciitis,^{23,24} but this is also unproved. The role of various management strategies should be considered in the light of the self-limiting nature of the condition.

Physical Therapy

Many types of physical therapy have been proposed as treatments for plantar fasciitis.²⁴ Support for the use of ice, heat, and massage and for strengthening of the intrinsic muscles of the foot comes predom-

inantly from anecdotal data. Stretching of the calf muscles and plantar fascia and taping or strapping of the foot are commonly recommended, but these therapies have generally been assessed in combination with other interventions, making it difficult to interpret the results of any individual intervention. A recent trial involving 101 participants showed that heel pain was either eliminated or much improved at eight weeks in 24 of 46 patients (52 percent) who were treated with an exercise program to stretch the plantar fascia, as compared with 8 of 36 patients (22 percent) who reported such results after participating in a program to stretch the Achilles tendon.³⁰ However, the study was not blinded, there was a large difference in the dropout rate between the groups (28 percent in the group in which patients stretched the Achilles tendon and 10 percent in the group in which patients stretched the plantar fascia), and only those who completed the trial were included in the analysis. Two randomized, placebo-controlled trials^{31,32} did not demonstrate a benefit of using magnetic insoles, and small randomized, placebo-controlled trials²⁹ found no significant benefit of ultrasonography, laser treatment, iontophoresis, or exposure to an electron-generating device.

Orthotic Devices

A wide variety of prefabricated and custom-made orthoses, including heel pads and cups that are variously designed to elevate and cushion the heel, provide medial arch support, or both, are used to treat plantar fasciitis. There are no data on the efficacy of these devices as compared with placebo or no treatment, and the available data on their efficacy in comparison with that of other interventions are conflicting or limited. One study, involving 103 patients, compared mechanical treatment (taping and orthoses) with the use of a heel cup or antiinflammatory treatment (three corticosteroid injections administered at weekly intervals, plus nonsteroidal therapy). Among the 77 patients who completed the trial, mechanical treatment was more effective in achieving an outcome rated as "excellent" or "fair" at three months (reported for 19 of 27 patients, or 70 percent) than was use of the heel cup (7 of 23 patients, or 30 percent) or antiinflammatory treatment (9 of 27 patients, or 33 percent).³³ In a trial involving 236 participants, prefabricated shoe inserts (a silicone cone, felt pad, or rubber heel cup) were found to be superior both to using custom-made orthotic devices and to stretching alone. (The percentages

of patients whose condition had improved at eight weeks were 95 percent for a silicone-cone insert, 88 percent for a felt pad, 81 percent for a rubber heel cup, 68 percent for custom-made orthotic devices, and 72 percent for stretching alone.²)

Splinting and Walking Casts

The use of night splints, designed to keep the ankle in a neutral position with or without dorsiflexion of the metatarsophalangeal joints during sleep, has been evaluated in two randomized, controlled trials, with conflicting results.^{34,35} One trial involving 116 participants showed no benefit of a night splint worn for three months as compared with no treatment.³⁵ In contrast, a crossover trial involving 37 participants suggested a benefit of a night splint worn for one month as compared with no treatment.³⁴ However, a crossover design may not be a valid method for studying interventions for treatment of a self-limiting condition. A third trial involving 255 participants showed no benefit of a posterior tension splint used at night as compared with either custom-made orthoses or over-the-counter arch supports.³⁶ There are no published data from controlled trials of immobilization with casts or other devices. A retrospective review reported a recurrence of pain, usually within a month after cessation of the use of a plaster cast, in 11 of 24 patients (46 percent) for whom follow-up data were available.³⁷

Antiinflammatory Agents

Nonsteroidal antiinflammatory drugs are often used in practice, but randomized trials have not been conducted to assess their benefit. The injection of corticosteroids, usually mixed with local anesthetic and injected with the use of a medial approach, is another common treatment for heel pain.²⁹ Limited data suggest that this treatment provides only short-term pain relief. One trial, involving 91 participants, showed that 1 ml of prednisolone acetate (25 mg) with 1 ml of local anesthetic, injected with the use of a medial approach, resulted in significantly greater improvement in pain at one month than did injection of local anesthetic alone; the mean (\pm SD) changes in the pain score, measured on a 10-cm visual-analogue scale, were 2.0 ± 2.9 and 0.06 ± 3.0 , respectively.²⁹ At three and six months, there were no differences between the groups in pain measures, but a high rate of loss to follow-up precluded the drawing of conclusions. A tibial-nerve block given before injection did not appear to reduce the discomfort of the injection. One concern is that corticoste-

roid injections may be associated with an increased risk of rupture of the plantar fascia,^{38,39} although data to support this association are limited and inconclusive.^{13,38}

Extracorporeal Shock-Wave Therapy

Extracorporeal shock-wave therapy has been proposed as an alternative approach on the grounds that it may stimulate healing of soft tissue and inhibit pain receptors.⁴⁰ However, the available data do not provide substantive support for its use. Of six randomized, double-blind, placebo-controlled trials assessing the efficacy of extracorporeal shock-wave therapy,⁴⁰⁻⁴⁵ three studies (involving 166, 272, and 88 participants) showed no benefit,^{40,43,44} and two studies (involving 150 and 302 participants) reported small benefits that were of questionable clinical importance.^{41,42} A sixth trial, involving 45 runners, showed that extracorporeal shock-wave therapy, as compared with placebo, resulted in a significant reduction in the score for pain on first walking in the morning (a mean reduction of 2.6 on a 10-cm visual-analogue scale) at six months.⁴⁵

Surgery

Surgery may be considered for a small subgroup of carefully selected patients who have persistent, severe symptoms despite nonsurgical intervention for at least 6 to 12 months. The surgical procedures used for plantar fasciitis include variations of open or closed partial or complete plantar fascia release with or without calcaneal spur resection, excision of abnormal tissue, and nerve decompression.^{46,47} In case series, favorable outcomes were reported in more than 75 percent of patients who underwent surgery, although the recovery times varied and were sometimes months,⁴⁸ and persistent pain occurred in up to a quarter of patients who were followed for an average of two or more years.^{48,49} Potential complications include transient swelling of the heel pad, calcaneal fracture, injury of the posterior tibial nerve or its branches, and flattening of the longitudinal arch with resultant midtarsal pain. As compared with open release surgery, closed procedures may allow for more rapid recovery and resumption of usual activities,^{47,50} although the risk of nerve injury may be higher with endoscopic release and other closed procedures than with other approaches.⁵¹ Controlled trials are required to verify these findings.

PREVENTION

The efficacy of preventive strategies such as stretching exercises and control of the intensity of running

(e.g., limiting distance, frequency, and duration) is not known.⁵² A randomized trial that involved 390 male infantry recruits showed that improved shock absorption, obtained with the use of basketball shoes rather than standard infantry boots, during 14 weeks of training resulted in a significantly lower incidence of foot-overuse injuries (including heel pain, arch pain, and metatarsalgia but not metatarsal stress fracture). Overuse injuries occurred in 15.5 percent of the men who wore basketball shoes, as compared with 29.1 percent of those who wore standard infantry boots (relative risk, 0.53; 95 percent confidence interval, 0.36 to 0.80).⁵³

AREAS OF UNCERTAINTY

The cause or causes of plantar fasciitis remain uncertain. The potential role, if any, of imaging studies in guiding treatment, monitoring the course of the disorder, or both has yet to be clarified; currently, imaging techniques have little role in routine clinical practice. One study showed that ultrasound-guided corticosteroid injections had the same outcome as injections administered without such guidance.⁵⁴ Randomized clinical trials are needed to assess whether the commonly used treatments are beneficial in modifying the natural history of plantar fasciitis.

GUIDELINES

The American College of Foot and Ankle Surgeons issued a practice guideline in 2001 that is based on expert opinion.⁵⁵ The recommendations generally reflect current clinical practice, but most of them are of unproven benefit. Initial treatment options include administering nonsteroidal antiinflammatory drugs, padding and strapping the foot, injecting corticosteroids, regularly stretching the calf muscles, avoiding the use of flat shoes and walking barefoot, applying ice to the affected area, using over-the-counter arch supports and heel cushions, and limiting activities. Second-line options for those patients who have not had any improvement after six weeks include the use of custom orthotic devices, night splints, and immobilization of the foot with casts and other devices during activity for four to six weeks. Plantar fasciotomy is reserved for patients in whom conservative measures have failed; removal of the plantar spur is not believed to add to the success of surgery.

A position statement regarding endoscopic and open heel surgery that was issued by the American

Orthopaedic Foot and Ankle Society recommends that endoscopic plantar fascia release not be performed if there is nerve compression.⁵¹ This recommendation is based on suggestions that the risk of nerve injury may be higher with endoscopic procedures than with open procedures.

CONCLUSIONS
AND RECOMMENDATIONS

Patients, such as the woman in the introductory vignette, who have symptoms and signs consistent with plantar fasciitis — including heel pain that worsens on first walking in the morning and tenderness over the anteromedial aspect of the inferior heel — should be informed that the condition is self-limiting and that in more than 80 percent of patients, the symptoms will resolve within a year, regardless of therapy. Since there is limited evidence about the value of treatments for plantar fasciitis, a reasonable approach to intervention is to start with

patient-directed, low-risk, minimal-cost interventions, such as regularly stretching the calf muscles and the plantar fascia, avoiding flat shoes and walking barefoot, using over-the-counter arch supports and heel cushions, and limiting extended physical activities. A trial of nonsteroidal antiinflammatory drugs may be reasonable. Corticosteroid injections may provide a short-term benefit.

More costly treatments — such as the use of custom-made orthotic devices, night splints, and immobilization with casts or other devices — may be options for patients in whom the condition does not improve, although the value of these treatments is currently uncertain. Surgery should be reserved for those patients whom conservative therapy has not helped after 6 to 12 months. In the absence of data to guide the surgical approach, referral to a surgeon with expertise in treating patients with plantar fasciitis is recommended.

I am indebted to Daniel Riddle, Stephen Hall, and Peter Lowthian for their insightful comments.

REFERENCES

1. McCarthy DJ, Gorecki GE. The anatomical basis of inferior calcaneal lesions: a cryomicrotomy study. *J Am Podiatry Assoc* 1979;69:527-36.
2. Pfeffer G, Bacchetti P, Deland J, et al. Comparison of custom and prefabricated orthoses in the initial treatment of proximal plantar fasciitis. *Foot Ankle Int* 1999;20:214-21.
3. McBryde AM Jr. Plantar fasciitis. *Instr Course Lect* 1984;33:278-82.
4. Ballas MT, Tylko J, Cookson D. Common overuse running injuries: diagnosis and management. *Am Fam Physician* 1997;55:2473-84.
5. Clement DB, Taunton JE, Smart GW, McNicol KL. A survey of overuse running injuries. *Physician Sportsmed* 1981;9(5):47-58.
6. Sadat-Ali M. Plantar fasciitis/calcaneal spur among security forces personnel. *Mil Med* 1998;163:56-7.
7. Furey JG. Plantar fasciitis: the painful heel syndrome. *J Bone Joint Surg Am* 1975;57:672-3.
8. Lapidus PW, Guidotti FP. Painful heel: report of 323 patients with 364 painful heels. *Clin Orthop* 1965;39:178-86.
9. Taunton JE, Ryan MB, Clement DB, McKenzie DC, Lloyd-Smith DR, Zumbo BD. A retrospective case-control analysis of 2002 running injuries. *Br J Sports Med* 2002;36:95-101.
10. Chigwanda PC. A prospective study of plantar fasciitis in Harare. *Cent Afr J Med* 1997;43:23-5.
11. Leach RE, Seavey MS, Salter DK. Results of surgery in athletes with plantar fasciitis. *Foot Ankle* 1986;7:156-61.
12. Lemont H, Ammirati KM, Usen N. Plantar fasciitis: a degenerative process (fasciosis) without inflammation. *J Am Podiatr Med Assoc* 2003;93:234-7.
13. Jarde O, Diebold P, Havet E, Boulu G, Vernois J. Degenerative lesions of the plantar fascia: surgical treatment by fasciectomy and excision of the heel spur: a report on 38 cases. *Acta Orthop Belg* 2003;69:267-74.
14. Gill LH, Kiezbak GM. Outcome of non-surgical treatment for plantar fasciitis. *Foot Ankle Int* 1996;17:527-32. [Erratum, *Foot Ankle Int* 1996;17:722.]
15. Prichasuk S, Subhadrabandhu T. The relationship of pes planus and calcaneal spur to plantar heel pain. *Clin Orthop* 1994;306:192-6.
16. Rano JA, Fallat LM, Savoy-Moore RT. Correlation of heel pain with body mass index and other characteristics of heel pain. *Foot Ankle Surg* 2001;40:351-6.
17. Riddle DL, Pulisic M, Pidcoe P, Johnson RE. Risk factors for plantar fasciitis: a matched case-control study. *J Bone Joint Surg Am* 2003;85:872-7. [Erratum, *J Bone Joint Surg Am* 2003;85:1338.]
18. Onuba O, Ireland J. Plantar fasciitis. *Ital J Orthop Traumatol* 1986;12:533-5.
19. Rome K. Anthropometric and biomechanical risk factors in the development of plantar heel pain — a review of the literature. *Phys Ther Rev* 1997;2:123-34.
20. Martin RL, Irrgang JJ, Conti SF. Outcome study of subjects with insertional plantar fasciitis. *Foot Ankle Int* 1998;19:803-11.
21. Wolgin M, Cook C, Graham C, Mauldin D. Conservative treatment of plantar heel pain: long-term follow-up. *Foot Ankle Int* 1994;15:97-102.
22. Davis PF, Severud E, Baxter DE. Painful heel syndrome: results of nonoperative treatment. *Foot Ankle Int* 1994;15:531-5.
23. Singh D, Angel J, Bentley G, Trevino SG. Plantar fasciitis. *BMJ* 1997;315:172-5.
24. Young CC, Rutherford DS, Niedfeldt MW. Treatment of plantar fasciitis. *Am Fam Physician* 2001;63:467-78. [Erratum, *Am Fam Physician* 2001;64:570.]
25. Groshar D, Alpersom M, Toubi A, Gorenberg A, Liberson A, Bar-Meir E. Plantar fasciitis: detection with ultrasonography versus bone scintigraphy. *Foot* 2000;10:164-8.
26. Gibbon WW, Long G. Ultrasound of the plantar aponeurosis (fascia). *Skeletal Radiol* 1999;28:21-6.
27. Berkowitz JF, Kier R, Rudicel S. Plantar fasciitis: MR imaging. *Radiology* 1991;179:665-7.
28. McGonagle D, Marzo-Ortega H, O'Connor P, et al. The role of biomechanical factors and HLA-B27 in magnetic resonance imaging-determined bone changes in plantar fascia enthesopathy. *Arthritis Rheum* 2002;46:489-93.
29. Crawford F, Thomson C. Interventions for treating plantar heel pain. *Cochrane Database Syst Rev* 2003;3:CD000416.
30. DiGiovanni BF, Nawoczenski DA, Lintal ME, et al. Tissue-specific plantar fascia-stretching exercise enhances outcomes in patients with chronic heel pain: a prospective, randomized study. *J Bone Joint Surg Am* 2003;85:1270-7.
31. Caselli MA, Clark N, Lazarus S, Velez Z, Venegas L. Evaluation of magnetic foil and PPT insoles in the treatment of heel pain. *J Am Podiatr Med Assoc* 1997;87:11-6.

32. Winemiller MH, Billow RG, Laskowski ER, Harmsen WS. Effect of magnetic vs sham-magnetic insoles on plantar heel pain: a randomized controlled trial. *JAMA* 2003;290:1474-8. [Erratum, *JAMA* 2004;291:46.]
33. Lynch DM, Goforth WP, Martin JE, Odom RD, Preece CK, Kotter MW. Conservative treatment of plantar fasciitis: a prospective study. *J Am Podiatr Med Assoc* 1998;88:375-80.
34. Powell M, Post WR, Keener J, Wearden S. Effective treatment of chronic plantar fasciitis with dorsiflexion night splints: a crossover prospective randomized outcome study. *Foot Ankle Int* 1998;19:10-8.
35. Probe RA, Baca M, Adams R, Preece C. Night splint treatment for plantar fasciitis: a prospective randomized study. *Clin Orthop* 1999;368:190-5.
36. Martin JE, Hosch JC, Goforth WP, Murff RT, Lynch DM, Odom RD. Mechanical treatment of plantar fasciitis: a prospective study. *J Am Podiatr Med Assoc* 2001;91:55-62.
37. Tisdell CL, Harper MC. Chronic plantar heel pain: treatment with a short leg walking cast. *Foot Ankle Int* 1996;17:41-2.
38. Acevedo JI, Beskin JL. Complications of plantar fascia rupture associated with corticosteroid injection. *Foot Ankle Int* 1998;19:91-7.
39. Sellman JR. Plantar fascia rupture associated with corticosteroid injection. *Foot Ankle Int* 1994;15:376-81.
40. Speed CA, Nichols D, Wies J, et al. Extracorporeal shock wave therapy for plantar fasciitis: a double blind randomised controlled trial. *J Orthop Res* 2003;21:937-40.
41. Ogdan JA, Alvarez R, Levitt R, Cross GL, Marlow M. Shock wave therapy for chronic proximal plantar fasciitis. *Clin Orthop* 2001;387:47-59.
42. Buch M, Knorr U, Fleming L, et al. Extracorporeale Stoßwellentherapie beim symptomatischen Fersensporn: eine Übersicht. *Orthopade* 2002;31:637-44.
43. Buchbinder R, Ptasznik R, Gordon J, Buchanan J, Prabaharan V, Forbes A. Ultrasound-guided extracorporeal shock wave therapy (ESWT) for plantar fasciitis: a randomized controlled trial. *JAMA* 2002;288:1364-72.
44. Haake M, Buch M, Schoellner C, et al. Extracorporeal shock wave therapy for plantar fasciitis: randomised controlled multicentre trial. *BMJ* 2003;327:75.
45. Rompe JD, Decking J, Schoellner C, Nafe B. Shock wave application for chronic plantar fasciitis in running athletes: a prospective, randomized, placebo-controlled trial. *Am J Sports Med* 2003;31:268-75.
46. DeMaio M, Paine R, Mangine RE, Drez D Jr. Plantar fasciitis. *Orthopedics* 1993;16:1153-63.
47. Barrett SJ, O'Malley R. Plantar fasciitis and other causes of heel pain. *Am Fam Physician* 1999;59:2200-6.
48. Davies MS, Weiss GA, Saxby TS. Plantar fasciitis: how successful is surgical intervention? *Foot Ankle Int* 1999;20:803-7.
49. Sammarco GJ, Helfrey RB. Surgical treatment of recalcitrant plantar fasciitis. *Foot Ankle Int* 1996;17:520-6.
50. Kinley SF, Frascone S, Calderone D, Wertheimer SJ, Squire MA, Wiseman FA. Endoscopic plantar fasciotomy versus traditional heel spur surgery: a prospective study. *J Foot Ankle Surg* 1993;32:595-603.
51. Heel pain. In: *Orthopaedic knowledge update: foot and ankle 2*. Rosemont, Ill.: American Academy of Orthopaedic Surgeons, 1998:175-83.
52. Yeung EW, Yeung SS. A systematic review of interventions to prevent lower limb soft tissue running injuries. *Br J Sports Med* 2001;35:383-9.
53. Milgrom C, Finestone A, Shlamkovitch N, et al. Prevention of overuse injuries of the foot by improved shoe shock attenuation: a randomized prospective study. *Clin Orthop* 1992;281:189-92.
54. Kane D, Greaney T, Shanahan M, et al. The role of ultrasonography in the diagnosis and management of idiopathic plantar fasciitis. *Rheumatology (Oxford)* 2001;40:1002-8.
55. The diagnosis and treatment of heel pain. *J Foot Ankle Surg* 2001;40:329-40.

Copyright © 2004 Massachusetts Medical Society.

IMAGES IN CLINICAL MEDICINE

The *Journal* welcomes consideration of new submissions for Images in Clinical Medicine. Instructions for authors and procedures for submissions can be found on the *Journal's* Web site at www.nejm.org. At the discretion of the editor, images that are accepted for publication may appear in the print version of the *Journal*, the electronic version, or both.