

Recognizing Normal Heart Murmurs: A Logic-based Mnemonic

A logic-based mnemonic for the auscultatory diagnosis of nonpathologic murmurs, which I developed for teaching medical students and house staff, is presented with the hope of improving the auscultatory skills of primary care pediatric practitioners. The objective is positive identification of nonpathologic murmurs rather than diagnosis by exclusion. The auscultatory features of these murmurs are largely determined by their causative mechanisms. The logic, therefore, is based on an understanding of these mechanisms so that the listener will know why these murmurs have their characteristic sound features and specifically what to listen for. The logic can also be used in explaining nonpathologic murmurs to parents. The mnemonic device should reduce the need for rote memorization.

Heart murmurs are present in most pediatric patients, and almost all are nonpathologic. Yet, the most common reason for referral to many pediatric cardiologists is for the evaluation of a heart murmur, two thirds of which are deemed normal.^{1,2} I believe that improving the accuracy of auscultation by primary care practitioners and improving their confidence in recognizing normal murmurs will decrease referrals to pediatric cardiologists, without underreferral of patients with heart disease. This outcome would be of significant psychologic and economic benefit to patients and their families.

In referring to nonpathologic murmurs, the commonly used terms are innocent, functional, and normal. I prefer the latter. Perhaps, because "normal" is a less technical, more familiar word to parents, to me it seems easier for them to understand and accept the benign nature of these murmurs with this terminology. The formulation of the logic begins with a consideration of causative mechanisms.

GENESIS OF HEART MURMURS

A heart murmur is a continuous series of sounds, with a variable number of different sound wave frequencies present at each instant. The wave frequency content of a murmur determines, to a large extent, its quality, pitch, and loudness.

The auditory quality of a murmur, an important element in differential diagnosis, is related to its spectrum or mix of frequencies. The clinical assessment of quality, however, is subjective, and there is no consensus on a descriptive terminology. In 1955, McKusick et al,³ using spectral phonocardiographic analysis of heart murmurs, linked quality to frequency mix and classified murmurs as either "musical" or "noisy." A musical murmur, similar to a musical tone, has only a fundamental frequency and

one or more harmonic overtones. A noisy murmur has a mix of random, harmonically unrelated frequencies. Building on this terminology, my practice is to describe the quality of a murmur by choosing the appropriate adjective from the following continuum: musical; somewhat musical; or slightly, moderately, or very noisy.

The pitch of a murmur is directly related to its frequency level and is described as low, medium, or high. Loudness is, in part, directly related to frequency level and is graded from 1 to 6.

Doppler echocardiography has been able to demonstrate the characteristics of blood flow in different parts of the heart and great vessels. In a flow channel that is straight and unobstructed, red blood cells are flowing in tandem, at about the same velocity. This type of flow is termed laminar or nondisturbed. As a flow channel narrows, flow velocity increases. When a certain level of constriction occurs, or if flow velocity increases sufficiently, flow characteristics at this point change. Laminar flow is disrupted, and red blood cells move simultaneously in different directions and with different velocities, creating disturbed or turbulent flow.

A heart murmur is produced when the contractions of the heart, and the associated pulsatile blood flow, produce enough tissue vibrations to be audible on the surface of the chest. The means by which these vibrations or sound waves are generated, and the identity of the tissues that vibrate, have been studied since murmurs were first described and are still being debated.⁴⁻⁶ Murmurs have been ascribed to vibrations produced directly by disturbed or turbulent blood flow, to indirect effects of turbulent flow such as vibration of vessel walls, and to direct vibration of structures such as the myocardial wall, valves, chordae, papillary muscles, and ventricular bands or false tendons.

It seems reasonable to me to assume that some murmurs are produced by a single mechanism and others by more than one, and that the auditory characteristics of a murmur would be determined by its underlying mechanism(s). Disturbed blood flow, because it produces a wide spectrum of non-harmonically related sound frequencies, would produce a noisy murmur, with the degree of noise being related to the degree of flow disturbance. A vibrating structure that produces a narrow spectrum of harmonically related frequencies would produce a purely musical murmur.⁷ A combination of disturbed flow and a harmonically vibrating structure would produce a noisy murmur that has a musical component.

In the normal heart, Doppler echocardiography demonstrates that blood flow through the cardiac chambers and valve orifices occurs in a predominantly laminar fashion. However, there are sites along the blood flow pathway that I term "disproportionate-sized connections." At these sites, either a smaller blood vessel is connected to a larger one, or a larger vessel branches into a smaller one, or a cardiac chamber is connected to a smaller caliber great vessel. In 1959, Bruns⁴ called these sites "discontinuities" and theorized that they can increase the velocity of blood flow at these points and can cause

Received for publication May 3, 1996; accepted Sep 23, 1996.
Reprint requests to (S.O.S.) 3831 Deervale Dr, Sherman Oaks, CA 91403.
PEDIATRICS (ISSN 0031 4005). Copyright © 1997 by the American Academy of Pediatrics.

sufficient flow disturbance to produce a murmur. Many studies since then, using such techniques as intracardiac phonocardiography and echo and Doppler, have supported this concept. The velocity of blood flow at these sites, however, still remains within the normal range, below that which would be seen with flow through a pathologically narrowed valve or vessel. Thus the degree of blood flow disturbance (and the noisiness of the murmur produced) remains low and in general is not detectable by standard Doppler echocardiographic techniques. Also, this change in flow velocity could create vibrations in adjacent soft tissue structures, which could further contribute to sound generation. Concurrent harmonic vibration of a solid tissue structure could add a musical quality to the murmur.

NORMAL HEART MURMURS

My logic-based mnemonic for normal heart murmurs therefore begins with the concept that in the normal pediatric heart, at sites with disproportionate-sized connections, there is an increase in flow velocity, which can generate flow disturbance and tissue vibrations to produce audible sound.

There are five such sites, and these can be remembered easily by following the course of blood flow through the heart from the systemic veins to the aorta:

1. The connection of the jugular, subclavian, and innominate veins to the superior vena cava;
2. The connection of the right ventricle to the main pulmonary artery;
3. The connection of the main pulmonary artery to the right and left pulmonary artery branches;
4. The connection of the left ventricle to the aorta; and
5. The connection of the aortic arch to the brachiocephalic vessels.

Sound waves resulting from the changes in flow at each of these five sites are transmitted to different, specific areas on the surface of the chest or neck (Figure). Murmurs in these five areas in healthy pediatric patients were identified and well described more than 50 years ago.⁵ Formal follow-up studies⁸⁻¹⁰ and empiric clinical observation over the years have confirmed the benign nature of these murmurs.

Because their predominant causative mechanism is the same, the five normal murmurs have the following generic auscultatory characteristics:

1. The four murmurs produced by arterial connections are all midsystolic; the one murmur produced by venous connections is continuous through systole and diastole and often has diastolic accentuation;
2. The murmurs are not louder than grade 3 of 6 (moderately loud);
3. The pitch is low to medium; and
4. The murmurs are slightly or moderately noisy, never very noisy, and may have a musical component, if, as we postulate, there is also a harmonically vibrating structure.

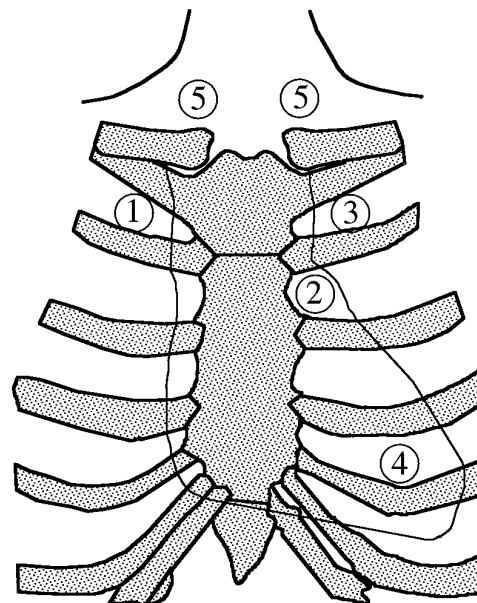


Figure. View of anterior chest wall with outline of cardiac silhouette superimposed on rib cage. Numbers indicate, in the course of blood flow through the heart, from systemic veins to the aorta, where each of the following five normal heart murmurs is heard best: 1, venous hum murmur (connection of jugular, subclavian, and innominate veins to the superior vena cava); 2, pulmonary flow murmur (connection of the right ventricle to the main pulmonary artery); 3, neonatal physiologic peripheral pulmonary artery stenosis murmur (branching of the main pulmonary artery); 4, precordial vibratory or Still's murmur (connection of the left ventricle to the aorta); and 5, supraclavicular or carotid bruit (connection of brachiocephalic vessels to the aortic arch).

In addition to these generic features, each of the normal murmurs has individual characteristics. The latter are determined by the type of disproportionate-sized connecting structures, their location in the circulatory system and within the chest, and the direction of transmission of the flow disturbance they create. In the course of blood flow through the heart, again, from the systemic veins to the aorta, the commonly used names and the individual features of the five normal murmurs are:

1. Venous hum murmur (connection of jugular, subclavian, and innominate veins to superior vena cava): continuous, often with diastolic accentuation; best heard below the right clavicle; may be transmitted to the left upper chest; disappears completely in the supine position, which differentiates it from the murmur of a patent ductus arteriosus or an arteriovenous fistula.
2. Pulmonary flow murmur (connection of right ventricle to main pulmonary artery): best heard in the second intercostal space at the left sternal border; may be transmitted slightly upward and downward; wide, fixed splitting of the second heart sound suggests the murmur is not normal and could be caused by an atrial septal defect.
3. Neonatal physiologic peripheral pulmonary artery stenosis murmur (branching of main pulmonary artery): best heard over the upper left sternal border; transmitted well to both infraclavicular areas, axillae, back, and slightly down the left sternal border; disappears in the first year.

4. Precordial vibratory or Still's murmur (connection of left ventricle to aorta): best heard medial to or at the apex; transmitted medially to the low and mid-left sternal border; typically has a much more musical component than any of the other normal murmurs, and often described in as varying terms, such as "vibratory," "twanging string," "groaning," and "moaning."
5. Supraclavicular or carotid bruit (connection of brachiocephalic vessels to aortic arch): best heard in the neck above the clavicles, usually bilateral; may be transmitted downward to infraclavicular areas.

CLINICAL APPLICATION

The generic and individual characteristics of the five normal murmurs that have been described are based on auscultation with the patient supine, at rest, and in a quiet room. A healthy child who is febrile, fearful, crying, or hyperactive will have an increased heart rate and cardiac output. The latter can produce more disturbed blood flow, make a normal murmur louder, noisier, less musical, and mislead the examiner into thinking the murmur is pathologic. Therefore, if the conditions of the examination are not optimal, the patient should be reevaluated.

In healthy individuals there are some sites with disproportionate-sized connections, such as the pulmonary veins entering the left atrium, which, perhaps because of poor transmission of sound waves, do not produce murmurs.

The fact that normal murmurs may coexist, although noted in the literature,¹¹⁻¹³ has, in my opinion, not been sufficiently emphasized. It is not unusual to hear a venous hum, a pulmonary flow murmur, a precordial vibratory murmur, and a supraclavicular bruit at the same time in a healthy child.

Although the objective is positive identification of the five normal murmurs, the clinician should also be aware of, and listen for, auscultatory clues suggesting cardiac disease. A recent study of patients referred to pediatric cardiologists for evaluation of a heart murmur¹⁴ identified six "cardinal clinical signs," which, if present, were independent statistical, but not absolute, predictors of cardiac disease. Of these the most significant, in my experience, are a pansystolic murmur, a harsh-quality murmur, an abnormal heart sound, and an early or midsystolic click. Less predictable, again, in my experience, is their fifth sign, a murmur of grade 3 or more in intensity, because normal murmurs can be moderately loud (grade 3). Similarly, their sixth sign, a murmur best heard over the upper left sternal border, is common in the healthy neonate. To this list I would add a diastolic murmur and a continuous murmur (other than a venous hum), which should always be considered pathologic.

In summary, the heart should be declared normal by a primary care practitioner when the history and general examination do not suggest heart disease, when one or more of the five normal murmurs is clearly identified, and when there are no auscultatory findings to suspect an abnormality. I agree with published studies^{1,15} that a confirmatory chest radio-

graph, electrocardiogram, or echocardiogram is not necessary. If there is doubt about the murmur being normal, then it has been shown^{2,16} that the most cost-effective next step is not laboratory testing but direct referral to a pediatric cardiologist.

CONCLUSION

The auscultatory positive recognition of normal heart murmurs is an important part of the pediatric examination, and if auscultation is done well by the primary care practitioner, it benefits the patient and the family and is very cost effective. In my experience, teaching and learning this skill can be more successful if it is based on an understanding of the mechanisms that are thought to produce normal murmurs and that are responsible for their auditory characteristics.

A mnemonic device has been presented to facilitate the recall of the five normal murmurs, based on the observation that each of these murmurs is related to a specific site along the path of blood flow through the heart, from the systemic veins to the aorta. Each of these sites has in common the feature that a larger vessel or chamber is directly connected to a smaller vessel or chamber, a characteristic termed disproportionate-sized connections, with the potential for creating disturbed blood flow, tissue vibrations, and a corresponding, very recognizable murmur.

SAMUEL O. SAPIN, MD

Department of Pediatrics

Southern California Permanente Medical Group
Panorama City, CA 91402

Department of Pediatrics

Division of Cardiology

University of California, Los Angeles

School of Medicine

Los Angeles, CA 90095

REFERENCES

1. Smythe JF, Teixeira OHP, Vlad P, Demers PP, Feldman W. Initial evaluation of heart murmurs: are laboratory tests necessary? *Pediatrics*. 1990;86:497-500
2. Danford DA, Nasir A, Gumbiner C. Cost assessment of the evaluation of heart murmurs in children. *Pediatrics*. 1993;91:365-368
3. McKusick VA, Murray GE, Peeler RG, Webb GN. Musical cardiovascular murmurs. *Bull Johns Hopkins Hosp*. 1955;97:136-176
4. Bruns DL. A general theory of the causes of murmurs in the cardiovascular system. *Am J Med*. 1959;27:360-374
5. Danford DA, McNamara DG. Innocent murmurs and sounds. In: Garson A, Bricker JT, McNamara DG, eds. *The Science and Practice of Pediatric Cardiology*. Philadelphia, PA: Lea & Febiger; 1990:1919-1928
6. Guntheroth WG. Musical murmurs. *Am J Cardiol*. 1992;69:840-841. Letter
7. Stein PD, Sabbah HN, Lakier JB. Origin and clinical relevance of musical murmurs. *Int J Cardiol*. 1983;4:103-112
8. Marienfeld CJ, Telles N, Silvera J, Nordesieck M. A 20-year follow-up study of "innocent" murmurs. *Pediatrics*. 1962;30:42-48
9. Weaver WF, Walker CHM. Innocent cardiovascular murmurs in the adult: a 16-year follow-up. *Circulation*. 1964;29:702-707
10. deMonchy C, Vander Hoeven GMA, Beneken JEW. Studies on innocent precordial murmurs in children. III. follow-up study in children with an innocent precordial vibratory murmur. *Br Heart J*. 1973;35:685-690
11. MacLaren MJ, Lochman AS, Pocock WA, Barlow JB. Innocent murmurs and third heart sounds in black children. *Br Heart J*. 1980;43:67-73
12. McNamara DG. Value and limitations of auscultation in the management of congenital heart disease. *Pediatr Clin North Am*. 1990;37:93-113
13. Harris JP. Evaluation of heart murmurs. *Pediatr Rev*. 1994;15:490-493
14. McCrindle BW, Shaffer KM, Kan JS, Zahka KG, Rowe SA, Kidd L. Cardinal clinical signs in the differentiation of heart murmurs in chil-